

Case report: Cutaneous nerve entrapment

Abdominal wall pain in an elderly patient

Roni Peleg, MD Pesach Shvartzman, MD

Diagnosis of chronic abdominal pain caused by cutaneous nerve entrapment can be elusive,¹ leading to unnecessary and expensive diagnostic tests, including potentially dangerous invasive procedures. Patients suffering from chronic abdominal wall pain are often misdiagnosed and treated as having a visceral source for their complaints.^{2,7}

Case report

A 72-year-old man presented with pain in his right upper abdomen that began 8 months before his consultation. The pain was exacerbated by postural changes and was partially alleviated by analgesics. He had had a cholecystectomy 28 years ago. The patient underwent a comprehensive workup, including ultrasound examination of the upper abdomen, gastroscopy, and colonoscopy, results of which were all within normal limits. No intra-abdominal pathology was identified that could explain the patient's prolonged pain.

On physical examination, tenderness was elicited by palpation of the right upper quadrant of the abdomen in the area of the Kocher incision from the cholecystectomy. In addition, hypoesthesia was found in the same region. Tenderness was exacerbated by gently pinching the skin without pressuring the internal organs (the Carnett sign). The Carnett sign indicates that the source of the pain is the abdominal wall. To assess the Carnett sign, the examiner places one hand on the tender point of the abdomen and the other on the patient's forehead, with the patient supine. When the patient attempts to rise against the examiner's resisting hand, the abdominal wall muscles contract. If the pain increases, pain originates in

Dr Peleg is a Lecturer and **Dr Shvartzman** is a Professor in the Department of Family Medicine at Ben-Gurion University of the Negev in Beer-Sheva, Israel.

This article has been peer reviewed.

Cet article a fait l'objet d'une évaluation externe.

Can Fam Physician 2001;47:788-789.

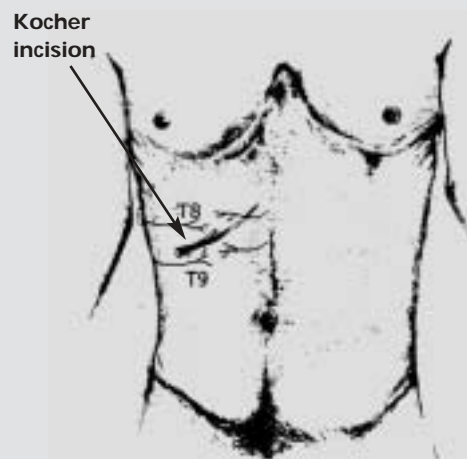
the abdominal wall. If the pain lessens, the source is more likely to be visceral.⁴

Local infiltration of the cutaneous nerve branches in the abdominal wall was performed. The infiltrate contained a mixture of 5 mL of 0.5% bupivacaine, 3 mL of 1% lidocaine hydrochloride, and 1 mL (6 mg) of betamethasone sodium phosphate and betamethasone acetate, which was injected subcutaneously with a 25-gauge spinal needle over the affected region. Before retraction, the needle was redirected under the skin, and three additional subcutaneous infiltrations were applied, producing a fan-shaped area of treatment (**Figure 1**). The patient reported immediate and complete pain relief, and he remained symptom-free for 1 year.

Discussion

The abdominal wall nerve entrapment syndrome is recognized as a complication of abdominal wall surgery, particularly after a Pfannenstiel incision, but also following other procedures.^{8,9} In one study that evaluated 79 patients with chronic abdominal wall

Figure 1. Segmental distribution of the cutaneous nerves and the pattern of injection for a nerve block



pain, 72 (94%) who were followed for at least 3 months experienced more than 50% pain relief with injection of anesthetic agents.¹

In four of the patients, abdominal pain was later diagnosed as caused by visceral disease. Thirty patients with confirmed chronic abdominal wall pain had diagnostic procedures to exclude visceral disease, at a cost of almost \$700 (US) per patient. In another study, about 15% had abdominal wall involvement as a cause of their pain.¹⁰ Thomson and Francis¹¹ reported that the abdominal wall was the source of abdominal pain in 23 of 24 patients who underwent laparotomy without evidence of visceral disorders.

The cause of nerve entrapment in the abdominal wall is unclear. It is known that pain is more common following surgery or trauma to the skin of the abdominal wall.^{1,8,9} One study found relatively more patients (65%) with the syndrome on the right side of the abdomen.¹ This might be due to overuse of this side, which is the dominant one in most patients. Changes occurring during pregnancy, such as thoracic wall structure and pressure on the abdominal wall resulting from uterine enlargement, or subcutaneous edema, might increase pressure on abdominal wall nerves.¹² Abdominal pain stemming from nerve entrapment is prolonged and usually reported as more severe than that from physical examination. There is hypoesthesia or hyperesthesia in the region of the pain, and the pain can be reproduced by gentle palpation without pressure on internal organs.¹² A proven examination for identifying abdominal wall pain was described by Carnett.⁴ Criteria for diagnosing nerve entrapment include:

- reproducing characteristic pain either during physical examination or by patient movement;
- absence of findings in other diagnostic tests; and
- unequivocal and complete response to nerve block.¹³

The accepted treatment for nerve entrapment syndrome today is local injection with infiltration of anesthetic agents together with steroids.^{1,12} The phenomenon of long-term or even permanent cure following anesthetic injection is not well understood.⁸

Indeed, in clinical practice, an uncommon presentation of a common problem, such as abdominal pain, is more likely than a common presentation of an uncommon disorder, such as nerve entrapment in the abdominal wall. This can lead to unnecessary and expensive diagnostic tests, including potentially dangerous invasive procedures.

In this case report, the abdominal wall pain that gradually increased in severity appeared in the area

Editor's key points

- Consider abdominal wall nerve entrapment when there is a scar and no other diagnostic finding.
- Nerve block usually cures the condition.

Points de repère du rédacteur

- On peut envisager un syndrome des défilés à la paroi abdominale lorsqu'il y a une cicatrice mais aucune autre conclusion diagnostique.
- Un blocage nerveux guérit habituellement le problème.

of an operation scar. There was evidence of shortening of body stature due to aging. We speculate that changes in the spine over the years caused changes in the structure of the chest wall, which eventually retracted a cutaneous nerve that was entrapped in the old scar tissue.

Conclusion

If nerve entrapment syndrome had been considered at an earlier stage, many unnecessary tests would have been avoided, and the patient would have had symptom relief in considerably less time. ❀

Correspondence to: Dr Roni Peleg, Department of Family Medicine, Ben-Gurion University of the Negev, PO Box 653, Beer-Sheva, 84105, Israel; telephone 972-7-6477436; fax 972-7-6477636; e-mail pelegr@bgumail.bgu.ac.il

References

1. Greenbaum DS, Greenbaum RB, Joseph JG, Natale JE. Chronic abdominal wall pain. Diagnostic validity and costs. *Dig Dis Sci* 1994;39:1935-41.
2. Gray DWR, Seabrook G, Dixon JM, Collin J. Is abdominal wall tenderness a useful sign in the diagnosis of non-specific abdominal pain? *Ann R Coll Surg Engl* 1988;70:233-4.
3. Hershfield NB. The abdominal wall: a frequently overlooked source of abdominal pain. *J Clin Gastroenterol* 1992;14:199-202.
4. Abdominal wall tenderness: could Carnett cut costs? [editorial]. *Lancet* 1991;337:1134.
5. Sidey JB. Trapped nerves [letter]. *BMJ* 1972;9:647.
6. Doduss TW, Boas RA. The abdominal cutaneous nerve entrapment syndrome. *N Z Med J* 1975;81:473-5.
7. Appelgate WV. Abdominal cutaneous nerve entrapment syndrome. *Surgery* 1972;71:118-24.
8. Sippo WC, Gomez AC. Nerve entrapment syndrome from lower abdominal surgery. *J Fam Pract* 1987;6:585-7.
9. Sippo WC, Burghardt A, Gomez AC. Nerve entrapment after Pfannenstiel incision. *Am J Obstet Gynecol* 1987;157:420-1.
10. Hall PN, Lee APB. Rectus nerve entrapment causing abdominal pain. *Br J Surg* 1988;75:917.
11. Thomson H, Francis DMA. Abdominal-wall tenderness: a useful sign in acute abdomen. *Lancet* 1977;2:1053-5.
12. Peleg R, Gohar J, Koretz M, Peleg A. Abnormal wall pain in pregnant women caused by thoracic lateral cutaneous nerve entrapment. *Eur J Obstet Gynecol Reprod Biol* 1997;74:169-71.
13. Spence EK, Rosato EF. The slipping rib syndrome. *Arch Surg* 1983;118:1330-2.