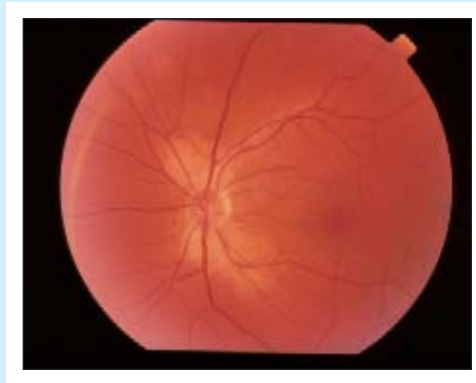
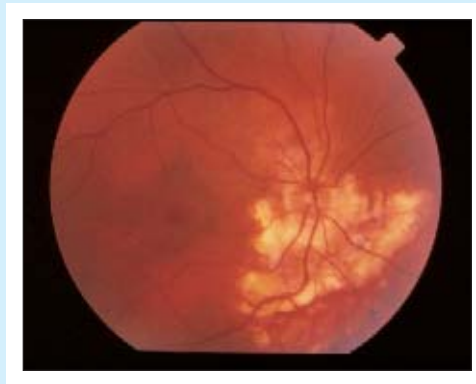

Ophthalmopproblem

John Cheung, MD Sanjay Sharma, MD, MSC, FRCSC

.....



A 42-year-old man presents with blurred vision in his right eye. He is otherwise healthy and has no other symptoms.

The appearance of the eye is compatible with the patient's having which of the following?

1. Diabetic retinopathy
2. Geographic choroidopathy
3. Optic neuritis
4. Iritis

Answer on page 1986

.....
Dr Cheung is a uveitis Fellow in the Department of Ophthalmology at McGill University in Montreal, Que. **Dr Sharma** is an Assistant Professor in the Departments of Ophthalmology and Epidemiology at Queen's University in Kingston, Ont.