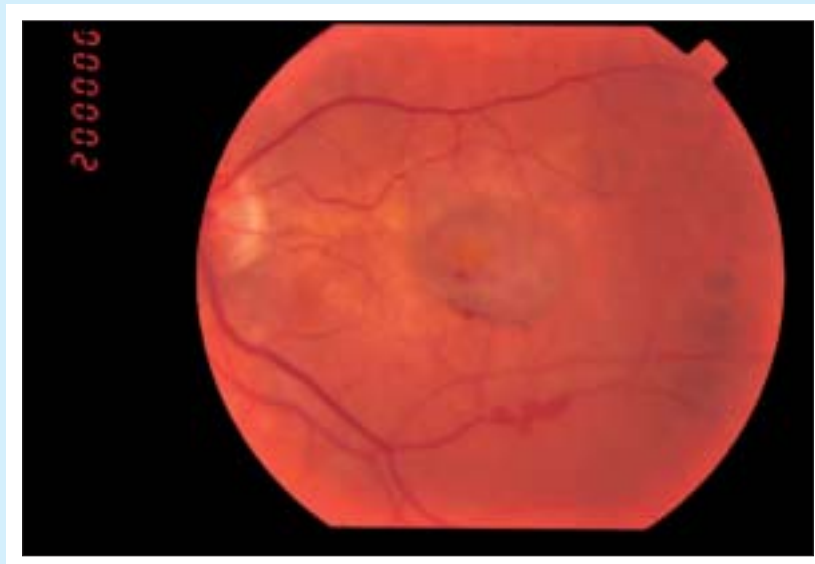



Ophthalmop problem

Sanjay Sharma, MD, MSC (EPID), FRCSC



A 73-year-old man complains of loss of vision in his left eye. His visual acuity is recorded at 6/30 in this eye. He is known to have end-stage age-related macular degeneration in the other eye. Systemic diseases include hypertension and diabetes mellitus.

Which of the following treatments should the patient receive?

1. Periocular steroids
2. Thermal laser photocoagulation
3. Photodynamic therapy with verteporfin
4. No treatment

Answer on page 963

.....
Dr Sharma is an Assistant Professor in the Departments of Ophthalmology and Epidemiology at Queen's University in Kingston, Ont.