

## Gastric dilatation as a cause of acute respiratory distress

W.E. Osmun MD MCISc CCFP Julie Copeland MD CCFP

**G**astric dilatation is a rare cause of acute dyspnea. The clinical presentation can be confusing, as gastric dilatation causing dyspnea usually occurs in the presence of numerous comorbidities. It is important that physicians keep gastric dilatation in mind as a cause of acute dyspnea, as the dyspnea might improve dramatically with decompression of the stomach.

### Case description

An 86-year-old man developed acute dyspnea in a community hospital. He suffered from numerous morbidities: chronic renal failure, requiring peritoneal dialysis; inoperable ischemic heart disease; congestive heart failure; gastroesophageal reflux; hyperlipidemia; and a right pleural effusion, requiring drainage. At the request of the nursing staff, the hospitalist attended the patient late in the evening. The patient had developed acute dyspnea. Before the physician's arrival, the nursing staff had administered salbutamol and ipratropium, with no effect.

During the preceding day, he had complained of epigastric discomfort and nausea. He had 1 episode of vomiting that day. Measurement of his vital signs revealed the following: pulse of 136 beats/min, respiratory rate (RR) of 26 breaths/min, and blood pressure (BP) of 129/70 mm Hg. On admission his vital signs had been the following: pulse of 77 beats/min, RR of 12 breaths/min, and BP of 111/64 mm Hg. His oxygen saturation was 92%; on admission it had been 96%.

The right lung had decreased air entry with wheeze from the previously documented pleural effusion. The left lung had decreased air entry in the base and was diffusely wheezy. An electrocardiogram revealed no acute ischemic changes. A chest x-ray scan revealed the previously noted pleural effusion on the right and a large gastric bubble pushing on the left diaphragm (**Figure 1**). There was no intestinal dilatation or evidence of any other air fluid levels. A nasogastric tube was placed and subsequently drained 1 L of fluid. The patient had prompt relief of his symptoms. The wheeze disappeared from his lungs and the air entry returned to normal on the left. His pulse dropped to

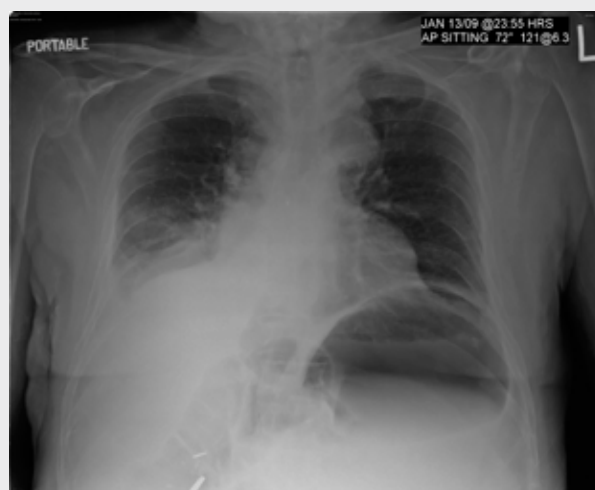
107 beats/min; his RR was 20 breaths/min and his BP was 122/57 mm Hg. The following morning an x-ray scan revealed a diminished gastric bubble and no evidence of free air or bowel obstruction. The nasogastric tube was removed 2 days after insertion, with no sequelae.

### Discussion

The causes of gastric dilatation, which can occur in all age groups, are poorly understood. Gastric dilatation, however, rarely causes serious difficulties and is self-limiting. It can cause dyspnea either postoperatively or as a result of an underlying structural abnormality.

This case is unusual in that the patient was not suffering from a postoperative ileus and did not have an underlying structural abnormality, in the form of a hiatal or diaphragmatic hernia, or a skeletal abnormality, such as kyphoscoliosis; but he did have a pre-existing right pleural effusion and ischemic heart disease, both of which might have made him more susceptible to the loss of lung volume as a result of the enlarged stomach. He did not suffer from diabetes, which could have resulted in a gastroparesis. There was no cause ascertained for the dilatation. It could have been a result of anxiety causing aerophagia. While other morbidities contributed to the patient's

**Figure 1.** Chest x-ray scan revealing a pleural effusion on the right and a large gastric bubble pushing on the left diaphragm



This article has been peer reviewed.

Cet article a fait l'objet d'une révision par des pairs.

*Can Fam Physician* 2010;56:151-2

acute dyspnea, the dramatic relief of the patient's symptoms with decompression supports the gastric dilatation as the main cause.

Gastric dilatation usually only causes serious problems in the context of other structural abnormalities. If the dilatation occurs in the presence of a diaphragmatic or hiatal hernia, it can cause compression of the lungs and tracheal deviation.<sup>1-4</sup> Gastric rupture as a result of gastric dilatation has been reported to have caused death in patients with severe cerebral palsy. In these cases the dilatation might be caused by aerophagia as a result of autonomic neuropathy, malposition of the stomach, or severe kyphoscoliosis.<sup>5</sup> Gastric dilatation has been reported to cause sudden respiratory distress postoperatively as a result of abdominal compartment syndrome.<sup>6</sup> Postoperative ileus with subsequent gastric dilatation is not uncommon, although it usually resolves without serious sequelae; however, rarely it can cause sudden deterioration requiring prompt gastric decompression.<sup>7</sup>

### Conclusion

Early recognition of gastric dilatation with prompt decompression will usually result in immediate improvement in the patient's condition. It is important to keep gastric dilatation on the differential diagnosis for dyspnea, especially in the face of other comorbidities, which might distract the investigation but prove not to be the cause of the patient's distress. ❁

**Dr Osmun** is an Associate Professor and **Dr Copeland** is an Assistant Professor, both in the Department of Family Medicine at the University of Western Ontario in London.

**Competing interests**  
None declared

### Correspondence

**Dr W.E. Osmun**, RR #5, 22262 Mill Rd, Mount Brydges, ON N0L 1W0; telephone 519 264-2800; fax 519 264-2742; e-mail [ted@smhc.net](mailto:ted@smhc.net)

### References

1. Berkman N, Simon Z, Almog Y, Kramer MR. Acute gastric dilatation causing respiratory failure and "tension pneumothorax" in an elderly woman with a diaphragmatic hernia. *Chest* 1993;104(1):317-8.
2. Hanekamp LA, Toben FM. A pregnant woman with shortness of breath. *Neth J Med* 2006;64(3):84,95.

### EDITOR'S KEY POINTS

- Gastric dilatation causing dyspnea usually occurs in the presence of numerous comorbidities; therefore, the clinical presentation can be confusing. It is important to consider gastric dilatation in the differential diagnosis for dyspnea.
- Gastric dilatation can cause dyspnea either postoperatively or as a result of an underlying structural abnormality, although no underlying cause was determined in the case presented.
- Early recognition of gastric dilatation with prompt decompression will usually result in immediate improvement in the patient's condition.

### POINTS DE REPÈRE DU RÉDACTEUR

- La dilatation gastrique causant une dyspnée se produit habituellement en présence de nombreuses comorbidités; par conséquent, la présentation clinique peut porter à confusion. Il est important d'envisager la dilatation gastrique dans le diagnostic différentiel de la dyspnée.
- La dilatation gastrique peut causer de la dyspnée soit après une opération ou en conséquence d'une anomalie structurelle sous-jacente, bien qu'aucune cause sous-jacente n'ait été détectée dans le cas en cause.
- La reconnaissance hâtive de la dilatation gastrique avec une décompression rapide améliorera habituellement immédiatement l'état du patient.

3. Reardon DJ, Freschini A, Harrison M, Coulson C, Nangalia LL. Oesophageal dilatation due to a paraesophageal hernia and gastric volvulus as a cause of stridor. *Emerg Med J* 2007;24(10):734.
4. Narendranathan M, Kalam A. Respiratory distress during endoscopy—report of an unusual case. *Postgrad Med J* 1987;63(743):805-6.
5. Byard RW, Couper RT, Cohle S. Gastric distention, cerebral palsy and unexpected death. *J Clin Forensic Med* 2001;8(2):81-5.
6. Mahajna A, Mitkal S, Krausz MM. Postoperative gastric dilatation causing abdominal compartment syndrome. *World J Emerg Surg* 2008;3:7.
7. Lee LS, Lim NL. Severe acute gastric dilatation causing respiratory failure. *Singapore Med J* 2006;47(8):716-8.

