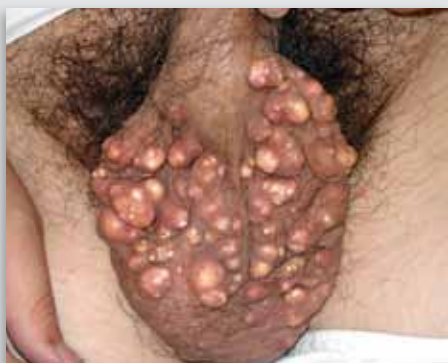

## Dermacase



### Can you identify this condition?

Engin Senel MD

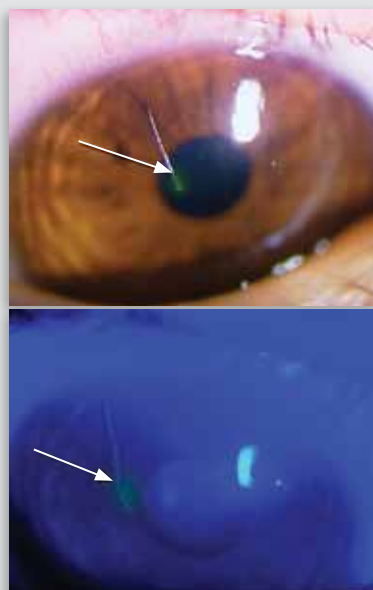
A 31-year-old man was referred to the dermatology clinic with pruritic subcutaneous nodules on his scrotum. The nodules first appeared 10 years before and slowly increased in size and number, with gradual onset of itching.

**The most likely diagnosis is**

1. Angiokeratoma
2. Idiopathic scrotal calcinosis
3. Steatocystoma multiplex
4. Testicular microlithiasis
5. Leukemia cutis

*Answer on page 672*

## Ophthaprobblem



### Can you identify this condition?

David Ehmann Kelly D. Schweitzer MD  
Stephanie Baxter MD

A 23-year-old woman presented with a 2-week history of pain, redness, and photophobia. She had no past ocular history and was a previous contact lens wearer. Her optometrist initially started her on a 1-week course of polymyxin B sulfate-gramicidin drops. Her symptoms only minimally resolved during this time, and they returned upon completion of the treatment. Her visual acuity and results of her eye examination were normal except for a strandlike lesion on the superficial cornea (shown above). In addition to this lesion, there were numerous smaller lesions visible on both corneas.

**The most likely diagnosis is**

1. Corneal ulcer or bacterial keratitis
2. Filamentary keratitis
3. Viral conjunctivitis
4. Herpetic keratitis

*Answer on page 673*