Diagnosis and management of eosinophilic esophagitis in children

Timothy Teoh Edmond S. Chan MD FRCPC Vishal Avinashi MD FRCPC Hin Hin Ko MD FRCPC Ran D. Goldman MD FRCPC

Abstract

Question After a few years of difficulty swallowing solids and feeling like food was getting stuck, a 13-year-old boy in my practice with peanut allergy and asthma was recently diagnosed with eosinophilic esophagitis (EoE). What is EoE and how is it diagnosed and managed?

Answer Eosinophilic esophagitis is an immune-mediated disease resulting in inflammation of the esophagus. It is increasing in prevalence and incidence in countries like Canada, and frequently occurs in children with other allergic conditions. Unexplained feeding difficulties, vomiting, and solid-food dysphagia, especially in boys with atopy, supports the possibility of having EoE. A formal diagnosis is obtained by reviewing esophageal biopsies obtained through upper endoscopy performed while the patient is taking a proton pump inhibitor. Once EoE has been established, management should involve working collaboratively with gastroenterology and allergy specialists. Medical or dietary treatments are acceptable therapeutic approaches.

Diagnostic et prise en charge de l'œsophagite éosinophilique chez les enfants

Résumé

Question Un garçon de 13 ans qui fréquente ma pratique souffre d'allergie aux arachides et d'asthme. Après quelques années de difficultés à avaler des aliments solides et d'impression que la nourriture reste coincée, il a récemment reçu un diagnostic d'œsophagite éosinophilique (EE). Qu'est-ce l'EE et comment la diagnostiquer et la prendre en charge?

Réponse L'œsophagite éosinophilique est une maladie à médiation immunitaire causant l'inflammation de l'œsophage. Sa prévalence et son incidence sont en hausse dans des pays comme le Canada et elle se produit fréquemment chez des enfants souffrant d'autres problèmes d'allergie. Des troubles d'alimentation, des vomissements et une dysphagie des aliments solides inexpliqués, surtout chez les garçons ayant une atopie, signalent la possibilité d'une EE. Le diagnostic formel se fait par l'analyse de biopsies œsophagiennes obtenues par endoscopie supérieure alors que le patient prend un inhibiteur de la pompe à protons. Lorsque le diagnostic d'EE est posé, sa prise en charge devrait se faire en collaboration avec des spécialistes en gastroentérologie et en allergies. Des traitements médicaux ou diététiques sont des approches thérapeutiques acceptables.

Eosinophilic esophagitis (EoE) is an immune- and antigen-mediated disease manifested by esophageal dysfunction due to eosinophilic-predominant inflammation.[1] Eosinophilic esophagitis is an increasingly recognized cause of dysphagia, as esophageal symptoms and eosinophilia are often misclassified as gastroesophageal reflux disease (GERD), in part owing to the nonspecificity of symptoms in younger patients.[1] A review of studies from 1976 to 2011 estimated a growing prevalence of EoE at 0.5 to 1 in 1000 globally, and an incidence of 10 cases per 10000 persons per year. Eosinophilic esophagitis is predominant in socioeconomically developed countries, but has the highest prevalence in the United States, Western Europe, and Australia, compared with Japan and China.[2] A recent study conducted at BC Children's Hospital in Vancouver found a paucity of East Asian (including Chinese and Japanese) pediatric patients, compared with white and South Asian patients, in the EoE cohort.[3] A transcriptome analysis of Japanese patients suggested that the pathogenetic processes of EoE in Japan and Western countries might be similar, highlighting the importance of environmental factors in this disease.[4] Canadian epidemiologic data are sparse, with one study estimating the incidence of pediatric and adult EoE in Calgary, Alta, to have been 11 cases in 10000 in 2008, a 40% annual increase from 2004.[5] The disease strongly favours male patients; the

male-female ratio is 3 to 1.[1] Although EoE can occur at any age, including in infancy, patients typically present in childhood (mean age 8.6 years) or in the third or fourth decades of life (mean age 38 years).[6]

Clinical manifestations

While clinical suspicion is needed to diagnose EoE, biopsy specimens are required for a formal diagnosis. In children, symptoms are nonspecific and vary by age. Toddlers often present with feeding difficulties with or without failure to thrive; vomiting is more common in older children, and dysphagia is common in adolescents. In adults, symptoms are more predictable, chiefly dysphagia, along with chest pain, food impaction, and upper abdominal pain.[1] Eosinophilic esophagitis has a strong association with allergy, especially among children; estimates suggest that as many as 75% of pediatric patients have a comorbid allergic disease (eg, immunoglobulin E [IgE]–mediated food allergy, asthma, atopic dermatitis, or allergic rhinitis), which is 3 times higher than the general population.[7] Thus a high clinical suspicion for EoE must be reserved for patients presenting with upper gastrointestinal symptoms concurrent with a history of atopy. Like most atopic conditions, EoE is a chronic disease and most pediatric patients will carry the disease into adulthood; however, EoE does not progress to other gastrointestinal diseases.[8]

Confirming the diagnosis of EoE

Pathologic information is essential for diagnosis of EoE, and secondary causes of esophageal eosinophilia should be excluded (**Box 1**).[9] In addition to symptoms, results of one or more esophageal biopsies must show eosinophil-predominant inflammation. This is defined as an esophageal biopsy specimen containing at least 15 eosinophils per high-powered field (HPF). Other histologic features might be present, such as eosinophilic microabscesses, surface layering of eosinophils, basal cell hyperplasia, lengthening of lamina propria papillae, intercellular edema, and lamina propria fibrosis. However, these are not specific.[1] Biopsies of the gastric antrum and duodenum are also recommended to rule out other conditions.[9]

Macroscopic features seen when performing endoscopy often include linear furrows, esophageal rings (or trachealization), pallor or decreased vasculature, or white plaques or exudates (**Figure 1**). In severe cases, esophageal strictures or delicate "crepe-paper" esophageal walls might be observed.[1]

Correlation of eosinophilia and macroscopic features is somewhat poor. In one study, a third of pediatric patients had an esophagus that visually appeared normal despite severe eosinophilia.[10] Although testing for total IgE level and peripheral eosinophilia might be a nonspecific indicator of atopy, there are inadequate data for the use of these tests as surrogate disease markers for EoE.[11]

Differentiating EoE from GERD

Eosinophilic esophagitis is differentiated from similar disorders, such as GERD and proton pump inhibitor (PPI)–responsive esophageal esophagitis, by persistent eosinophilia (>15 eosinophils/HPF) despite a trial of a PPI for 2 months or longer, including at the time of endoscopy.[1] Symptomatic response to PPI does not rule

Box 1. Selected criteria for diagnosis of EoE

The following are among the criteria for diagnosing EoE:

- Symptoms related to esophageal dysfunction
- Eosinophil-predominant inflammation on esophageal biopsy, characteristically consisting of a peak value of ≥15 eosinophils per high-powered field
- Mucosal eosinophilia is isolated to the esophagus and persists after a PPI trial
- Secondary causes of esophageal eosinophilia have been excluded
  - -eosinophilic gastrointestinal diseases (eg, eosinophilic gastritis, colitis)
  - -PPI-responsive esophageal eosinophilia
  - -celiac disease, Crohn disease
  - -hypereosinophilic syndrome

EoE—eosinophilic esophagitis, PPI—proton pump inhibitor.
Data from Dellon et al.[9]

Figure 1. Endoscopy findings typical of eosinophilic esophagitis: *Multiple concentric rings (white arrows), linear furrows (black arrows), and small white exudates (eosinophilic microabscesses) (circled).*

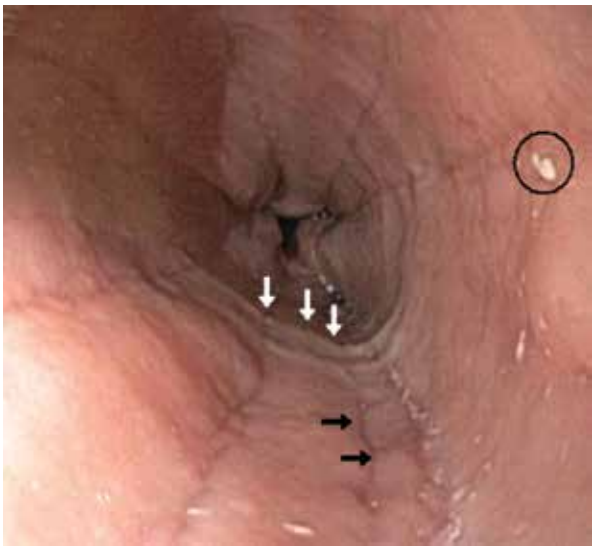

Image used with patient's permission.

in or rule out EoE.[12] Continuing the trial of the PPI leading up to the time of endoscopy potentially avoids time delay and a second endoscopy to confirm diagnosis.

Several features might suggest EoE rather than GERD, such as severe basal cell hyperplasia, eosinophilic microabscesses (4 or more eosinophils in a cluster), and surface layering of eosinophils. However, these are not specific enough to rule out GERD.[1,13] Likewise, maximum and minimum eosinophil counts distinguishing GERD from EoE are still under consideration. One study suggests that a peak count of less than 5 eosinophils per HPF might be interpreted as consistent with GERD, in the appropriate clinical setting.[11]

Treatment

Management of EoE is multidisciplinary and involves consultation with gastroenterology and allergy specialists. Treatment goals include symptom improvement, histologic remission, and improved quality of life. In addition to evaluating symptoms, patients should be reevaluated endoscopically after intervention to ensure histologic remission. Topical corticosteroids (ie, swallowed fluticasone or oral viscous budesonide) are an effective first-line pharmacologic option for EoE. Two separate randomized, double-blind, placebo-controlled trials of fluticasone propionate and oral viscous budesonide showed response rates in achieving histologic remission of 50% (n=36) and 87% (n=15) of patients, respectively.[14,15] Although rare, there have been reports of adrenal suppression with use of oral viscous budesonide that might not be dose dependent.[16] Systemic corticosteroids (eg, prednisone) are not recommended as a routine treatment of EoE owing to well-known adverse effects with long-term treatment, such as growth and bone abnormalities, psychiatric disturbances, adrenal suppression, and dyslipidemia. This therapy should be reserved for emergent cases requiring hospitalization, such as severe dysphagia resulting in weight loss or dehydration.[1,17]

Although the precise immune mechanisms explaining the role of foods in triggering EoE remain to be elucidated, dietary management has been shown to improve symptoms and histology once a formal diagnosis has been established.[1,10] Three dietary interventions exist for the treatment of EoE including elemental, directed elimination, or empiric elimination diets. Elemental diets are based on exclusive feeding with an amino acid–based formula.[18] However, the elemental diet reduces food variety, has an unpleasant taste, is costly, and is not easy to adhere to. Directed elimination diets use skin-prick testing and patch tests to identify and remove specific food triggers from the patient's diet.[19] Empiric elimination diets remove foods most commonly associated with triggering EoE. An example of empiric elimination would be the 6-food elimination diet, which eliminates the need for allergy testing and restricts cow's milk, soy, egg, wheat, peanuts and tree nuts, and seafood.[20] A meta-analysis of 33 studies comparing the efficacy of these 3 dietary therapies for achieving histopathologic remission concluded that the elemental diet was the most effective dietary approach (90.8% achieved histopathologic remission; n=429, 411 of whom were children), followed by the 6-food elimination diet (72.1%; n=197 patients). Data from 626 patients suggest that directed elimination diets have limited effect, with widely varied remission rates not exceeding 50%.[21] Responses to directed elimination and empiric elimination of foods have been studied in children more than adults.[22] A cow's milk–only elimination diet might be effective at inducing clinical and histologic remission in pediatric EoE patients, as shown in a small study, with similar response rates to a milk-only elimination diet (11 of 17 children, 65%) compared with empiric elimination (63%) and topical steroids (62%).[23]

Although skin-prick testing or specific IgE blood testing for foods has diagnostic value specifically for anaphylactic IgE-mediated food allergy, these tests have a high potential for false-positive or false-negative results in the case of EoE, with inconsistent data from different research centres.[24] The diagnostic value of skin-prick and atopy patch tests to identify food triggers compared with empiric approaches should be judiciously considered by a trained allergist, ideally in the setting of a multidisciplinary EoE management team.

Dietary therapy should be considered in all pediatric patients with EoE. Medical therapy can be considered in both children and adults. However, patient and family preferences, cost, and quality of life are essential factors when weighing the benefits and risks of different treatment choices.[1] The use of endoscopic dilation is reserved for symptomatic patients with strictures refractory to dietary or medical intervention.[1]

Competing interests
None declared

Correspondence
Dr Ran D. Goldman; e-mail **rgoldman@cw.bc.ca**

References

1. Liacouras CA, Furuta GT, Hirano I, Atkins D, Attwood SE, Bonis PA, et al. Eosinophilic esophagitis: updated consensus recommendations for children and adults. *J Allergy Clin Immunol* 2011;128(1):3-20.
2. Dellon ES. Epidemiology of eosinophilic esophagitis. *Gastroenterol Clin North Am* 2014;43(2):201-18. Epub 2014 Mar 19.
3. Teoh T, Koo C, Avinashi V, Chan ES. Characterization of ethnicity among children with eosinophilic esophagitis in British Columbia, Canada. *J Allergy Clin Immunol Pract* 2015 Jun 19. Epub ahead of print.
4. Shoda T, Morita H, Nomura I, Ishimura N, Ishihara S, Matsuda A, et al. Comparison of gene expression profiles in eosinophilic esophagitis (EoE) between Japan and Western countries. *Allergol Int* 2015;64(3):260-5. Epub 2015 Apr 9.
5. Syed AA, Andrews CN, Shaffer E, Urbanski SJ, Beck P, Storr M. The rising incidence of eosinophilic oesophagitis is associated with increasing biopsy rates: a population-based study. *Aliment Pharmacol Ther* 2012;36(10):950-8. Epub 2012 Sep 20.
6. Furuta GT, Liacouras CA, Collins MH, Gupta SK, Justinich C, Putnam PE, et al. Eosinophilic esophagitis in children and adults: a systematic review and consensus recommendations for diagnosis and treatment. *Gastroenterology* 2007;133(4):1342-63. Epub 2007 Aug 8.
7. Spergel JM. Eosinophilic esophagitis in adults and children: evidence for a food allergy component in many patients. *Curr Opin Allergy Clin Immunol* 2007;7(3):274-8.

8. Spergel JM, Brown-Whitehorn TF, Beausoleil JL, Franciosi J, Shuker M, Verma R, et al. 14 years of eosinophilic esophagitis: clinical features and prognosis. *J Pediatr Gastroenterol Nutr* 2009;48(1):30-6.
9. Dellon ES, Gonsalves N, Hirano I, Furuta GT, Liacouras CA, Katzka DA. ACG clinical guideline: evidenced based approach to the diagnosis and management of esophageal eosinophilia and eosinophilic esophagitis (EoE). *Am J Gastroenterol* 2013;108(5):679-92. Epub 2013 Apr 9.
10. Liacouras CA, Spergel JM, Ruchelli E, Verma R, Mascarenhas M, Semeao E, et al. Eosinophilic esophagitis: a 10-year experience in 381 children. *Clin Gastroenterol Hepatol* 2005;3(12):1198-206.
11. Genevay M, Rubbia-Brandt L, Rougemont AL. Do eosinophil numbers differentiate eosinophilic esophagitis from gastroesophageal reflux disease? *Arch Pathol Lab Med* 2010;134(6):815-25.
12. Spechler SJ, Genta RM, Souza RF. Thoughts on the complex relationship between gastroesophageal reflux disease and eosinophilic esophagitis. *Am J Gastroenterol* 2007;102(6):1301-6.
13. Mueller S, Neureiter D, Aigner T, Stolte M. Comparison of histological parameters for the diagnosis of eosinophilic oesophagitis versus gastro-oesophageal reflux disease on oesophageal biopsy material. *Histopathology* 2008;53(6):676-84.
14. Konikoff MR, Noel RJ, Blanchard C, Kirby C, Jameson SC, Buckmeier BK, et al. A randomized, double-blind, placebo-controlled trial of fluticasone propionate for pediatric eosinophilic esophagitis. *Gastroenterology* 2006;131(5):1381-91. Epub 2006 Aug 16.
15. Dohil R, Newbury R, Fox L, Bastian J, Aceves S. Oral viscous budesonide is effective in children with eosinophilic esophagitis in a randomized, placebo-controlled trial. *Gastroenterology* 2010;139(2):418-29. Epub 2010 May 7.
16. Harel S, Hursh BE, Chan ES, Avinashi V, Panagiotopoulos D. Adrenal suppression in children treated with oral viscous budesonide for eosinophilic esophagitis: a pilot study. *J Pediatr Gastroenterol Nutr* 2015 May 4. Epub ahead of print.
17. Liu D, Ahmet A, Ward L, Krishnamoorthy P, Mandelcorn ED, Leigh R, et al. A practical guide to the monitoring and management of the complications of systemic corticosteroid therapy. *Allergy Asthma Clin Immunol* 2013;9(1):30.
18. Kelly KJ, Lazenby AJ, Rowe PC, Yardley JH, Perman JA, Sampson HA. Eosinophilic esophagitis attributed to gastroesophageal reflux: improvement with an amino acid-based formula. *Gastroenterology* 1995;109(5):1503-12.
19. Spergel JM, Beausoleil JL, Mascarenhas M, Liacouras CA. The use of skin prick tests and patch tests to identify causative foods in eosinophilic esophagitis. *J Allergy Clin Immunol* 2002;109(2):363-8.
20. Kagalwalla AF, Sentongo TA, Ritz S, Hess T, Nelson SP, Emerick KM, et al. Effect of six-food elimination diet on clinical and histologic outcomes in eosinophilic esophagitis. *Clin Gastroenterol Hepatol* 2006;4(9):1097-102. Epub 2006 Jul 21.
21. Arias A, González-Cervera J, Tenias JM, Lucendo AJ. Efficacy of dietary interventions for inducing histologic remission in patients with eosinophilic esophagitis: a systematic review and meta-analysis. *Gastroenterology* 2014;146(7):1639-48. Epub 2014 Feb 15.
22. Gonsalves N, Kagalwalla AF. Dietary treatment of eosinophilic esophagitis. *Gastroenterol Clin North Am* 2014;43(2):375-83. Epub 2014 Mar 21.
23. Kagalwalla AF, Amsden K, Shah A, Ritz S, Manuel-Rubio M, Dunne K, et al. Cow's milk elimination: a novel dietary approach to treat eosinophilic esophagitis. *J Pediatr Gastroenterol Nutr* 2012;55(6):711-6.
24. Carr S, Watson W. Eosinophilic esophagitis. *Allergy Asthma Clin Immunol* 2011;7(Suppl 1):S8.

PRETx Pediatric Research in Emergency Therapeutics

Child Health Update is produced by the Pediatric Research in Emergency Therapeutics (PRETx) program (www.pretx.org) at the BC Children's Hospital in Vancouver, BC. **Mr Teoh** and **Drs Chan, Avinashi**, and **Ko** are members and **Dr Goldman** is Director of the PRETx program. The mission of the PRETx program is to promote child health through evidence-based research in therapeutics in pediatric emergency medicine..

Do you have questions about the effects of drugs, chemicals, radiation, or infections in children? We invite you to submit them to the PRETx program by fax at 604 875-2414; they will be addressed in future **Child Health Updates**. Published **Child Health Updates** are available on the *Canadian Family Physician* website (**www.cfp.ca**).