

# Schistosomiasis in a returning international traveler with cyclic fevers and diarrhea

Emily Greer DO MPH Kabir Harricharan Singh MD Gregory Blake MD MPH M. David Stockton MD MPH

**S**chistosomiasis is a parasitic disease caused by trematode flatworms of the genus *Schistosoma*.<sup>1</sup> The Centers for Disease Control and Prevention estimate that 85% of the world's cases of schistosomiasis are in Africa, where prevalence rates can exceed 50% in local populations.<sup>2</sup> The World Health Organization estimates more than 206.5 million people required preventive treatments for schistosomiasis in 2016, out of which more than 88 million were adequately treated.<sup>1</sup>

## Case

A 26-year-old, previously healthy man who had just returned from a 6-month mission trip to Uganda, Rwanda, and the Democratic Republic of the Congo presented initially to the family medicine clinic after 2 weeks of recurrent fevers and diarrhea. His first symptoms, while away, had included a rash on his legs after wading in Lake Victoria. While there, he was empirically treated with praziquantel and albendazole, as the area was known to be endemic for schistosomiasis and other parasitic infections.

Two months after his return to the United States, he developed nonbloody diarrhea, with a temperature

of 39.4°C accompanied by night sweats and myalgia. Initial laboratory studies included a complete blood count showing no anemia, thrombocytopenia, or leukocytosis, but revealing an elevated eosinophil count of  $27.7 \times 10^9/L$ ; a comprehensive metabolic panel with no abnormal results; and stool studies with negative results for ova, parasites, and bacterial growth, although a wet mount of the stool showed sheets of red and white blood cells and had positive findings for heme. The patient reported taking appropriate malaria prophylaxis and obtaining malaria tests. Polymerase chain reaction studies had negative results.

In the clinic he appeared fatigued, displayed postural hypotension with dehydration, and nearly fainted while walking. He was hospitalized for administration of intravenous fluids and consultation with the infectious disease and gastroenterology departments.

During his hospitalization he continued to have spikes of high fever, with a maximum temperature of 40.6°C. Repeat stool and blood tests, a malaria peripheral blood test drawn while febrile, and tests for *Entamoeba histolytica* antibodies all had negative results. Flexible sigmoidoscopy was performed

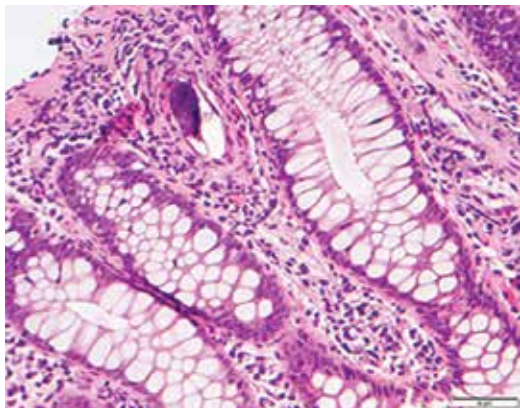
## Editor's key points

- ▶ Schistosomiasis is a parasitic disease caused by trematode flatworms of the genus *Schistosoma*. Acute schistosomiasis syndrome is characterized by symptoms of fever, diarrhea, abdominal pain, headache, myalgia, and cough, and occurs between 3 and 8 weeks after infection. Chronic intestinal schistosomiasis manifests as abdominal pain, diarrhea, hematochezia or melena, or hepatosplenomegaly.
- ▶ Schistosomiasis is most commonly diagnosed by detecting parasite eggs in stool or urine specimens or through rectal biopsy. Other potential laboratory findings include eosinophilia, thrombocytopenia, anemia, positive hemoccult stool findings, and hematuria. It is treated with praziquantel, an anthelmintic agent, and dosage depends on the species of parasite.
- ▶ Although the clinicians in this case performed a total of 5 stool ova and parasite excavations, none had positive findings, which made this case challenging to diagnose. A rectal biopsy confirmed a diagnosis of schistosomiasis. The patient made a full recovery after proper treatment with praziquantel.

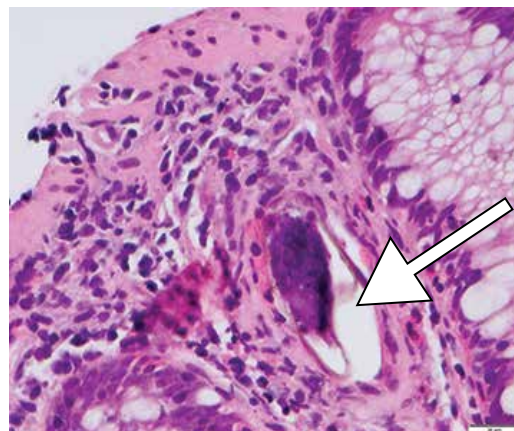
## Points de repère du rédacteur

- ▶ La schistosomiase est une maladie parasitaire causée par des vers plats de la classe des trématodes et du genre *Schistosoma*. Le syndrome aigu de la schistosomiase se caractérise par des symptômes de fièvre, de diarrhée, de douleurs abdominales, de céphalée et de myalgie, et il se produit de 3 à 8 semaines après l'infection. La schistosomiase intestinale chronique se manifeste sous forme de douleurs abdominales, de diarrhée, d'hématochésie ou de méléna, ou encore d'hépatosplénomégalie.
- ▶ La schistosomiase est le plus souvent diagnostiquée par la détection d'œufs de parasites dans des spécimens de selles ou d'urine, ou par une biopsie rectale. Parmi les autres constatations possibles en laboratoire figurent l'éosinophilie, la thrombocytopenie, l'anémie, des résultats positifs à la recherche de sang occulte dans les selles et l'hématurie. Elle est traitée avec du praziquantel, un agent anthelminthique, et la dose dépend de l'espèce du parasite.
- ▶ Même si, dans le présent cas, les cliniciens avaient effectué au total 5 tests de recherche d'œufs et de parasites dans les selles, aucun n'avait produit de résultats positifs, ce qui a compliqué le diagnostic. Une biopsie rectale a confirmé le diagnostic de schistosomiase. Le patient s'est entièrement rétabli après un traitement approprié avec du praziquantel.

**Figure 1.** Stain of a rectal biopsy specimen showing *Schistosoma mansoni* infection with classic intramucosal inclusion schistosomes, but without the granulomas consistent with an acute infection: Hematoxylin and eosin stain, original magnification  $\times 200$ .



**Figure 2.** Stain of a rectal biopsy specimen showing *Schistosoma mansoni* infection: Hematoxylin and eosin stain, original magnification  $\times 400$ . Arrow indicates the characteristic lateral spine only found in *S mansoni*.



and findings were consistent with nonspecific colitis. While awaiting stool and blood test results, he was empirically treated with 2, 3-g doses of praziquantel. Within 48 hours, the rectal biopsy results confirmed a diagnosis of *Schistosoma mansoni* infection, with classic intramucosal inclusion schistosomes, but without the granulomas consistent with an acute infection (Figures 1 and 2).

His final diagnosis at discharge was acute schistosomiasis syndrome (known as *Katayama fever*) from intestinal *S mansoni* infection.

Outpatient follow-up at 3 months showed normalization of his complete blood count results, with resolution of the eosinophilia. Stool ova and parasite studies continued to have negative results. He was given an additional 3-g dose of praziquantel 1 month after discharge to ensure resolution.

## Discussion

There are 5 important species of *Schistosoma*: intestinal *Schistosoma* consisting of *S mansoni*, *Schistosoma japonicum*, *Schistosoma intercalatum*, and *Schistosoma mekongi*, and urogenital *Schistosoma haematobium*.<sup>3</sup> The life cycle of the trematode begins in fresh water where the miracidia, which are released from eggs in the feces of individuals infected with the schistosome, penetrate specific snails as an intermediate host (Figure 3).<sup>4</sup> Cercariae from the snails are then released back into the water and penetrate the skin of humans, where they migrate to the venous system of either the gastrointestinal or the genitourinary tract.<sup>4</sup>

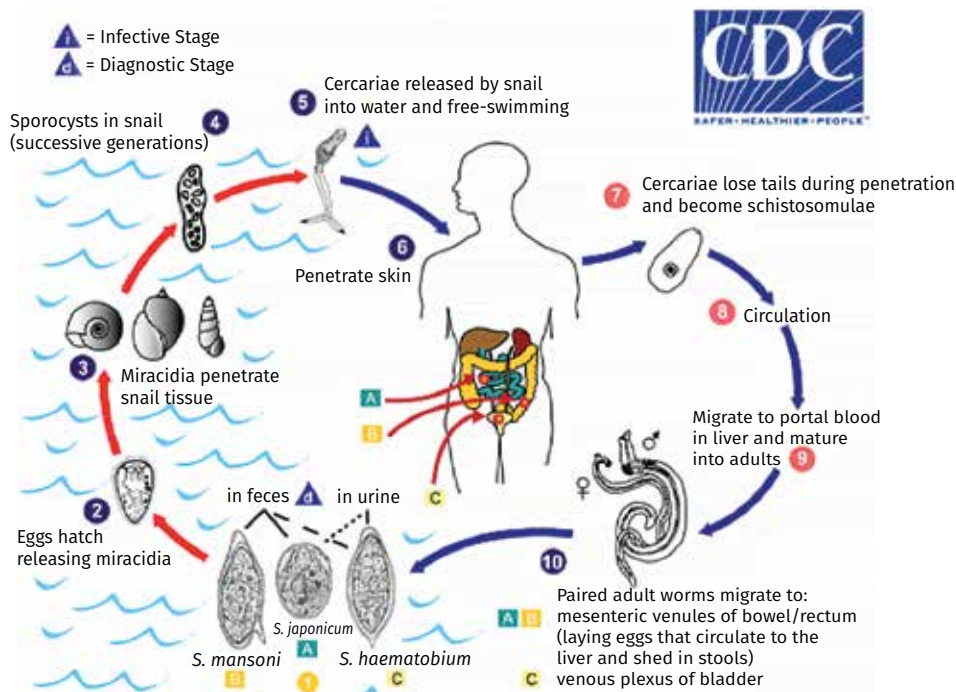
Acute schistosomiasis syndrome is characterized by symptoms of fever, diarrhea, abdominal pain, headache, myalgia, and cough, and occurs between 3 and 8 weeks after infection.<sup>5</sup> Only one or a few of these symptoms

might be present. Chronic infection in intestinal disease is manifested by abdominal pain, diarrhea, hematochezia or melena, or hepatosplenomegaly. Chronic urogenital schistosomiasis has clinical symptoms such as hematuria, genital lesions, and vaginal bleeding, and can lead to genitourinary tract organ fibrosis and bladder cancer.

Schistosomiasis is most commonly diagnosed by detecting parasite eggs in stool or urine specimens or through rectal biopsy.<sup>1</sup> Tests not used as routinely are antibody and antigen tests in blood or urine samples.<sup>6</sup> Less often, tests include serology, antigen detection, and molecular DNA polymerase chain reaction assays. Other potential laboratory findings include eosinophilic leukocytosis, thrombocytopenia, anemia, positive hemoccult stool findings, and hematuria. Treatment is with praziquantel, an anthelmintic agent. The treatment dosage varies from 40 mg/kg per day orally in 2 divided doses for 1 day, to 60 mg/kg per day orally in 3 divided doses on 1 day depending on the species being treated. Public health officials are working hard to eradicate and control spread of the disease through access to safe water, improved sanitation, hygiene education, and snail control.<sup>1</sup>

Illness, particularly fever, in returning travelers is a common clinical challenge for family physicians. Differential diagnoses include the common mosquito diseases of malaria and dengue fever; the rickettsial diseases such as typhus; and the water- and food-borne bacterial infections of typhoid and paratyphoid fevers. Common infections, such as respiratory, urinary, or skin infections, should, as always, be considered. Recurrent fevers are always treated as malaria until proven otherwise.

Although the history of this case was suggestive of *Schistosoma* infection, there were several aspects that made it unique: the previous treatment with praziquantel and the lack of positive stool findings.


**Figure 3. Life cycle of *Schistosoma* species**

In the history, the patient reported having taken a dose of praziquantel after exposure to a known *Schistosoma*-infested lake while abroad. The amount of praziquantel he received is unknown, as is whether the treatment was accurate in dosage and efficacy. Antibiotics and other medications abroad might lack the same potency and efficacy that they have in North America, which has strict governmental regulation policies.<sup>7</sup> The potential for the medicine this patient received to have been expired or of low potency exists. In addition to potential drug ineffectiveness, there is also specific timing for treatment of schistosomiasis. The incubation period of schistosomiasis ranges from 14 to 84 days, and praziquantel is most effective against the adult worm, which requires an established antibody response to the parasite.<sup>6</sup> Treatment typically should occur 6 to 8 weeks after exposure to contaminated water.<sup>6</sup> The patient was initially treated within the first week after exposure, so perhaps the treatment would have not been effective, as it was not yet directed against adult worms. Most of the disease can be eradicated with 1 course of treatment, but patients with a heavy disease burden might require retreatments 2 to 4 weeks after the initial dose.<sup>6</sup> Follow-up after initial treatment includes monitoring for re-emergence of clinical manifestations. Symptom resolution, eosinophilia resolution, and negative stool findings are indicators of disease eradication. Persistence of viable eggs requires repeated treatment.<sup>7</sup>

Another area of diagnostic concern was the consistent lack of findings from the stool studies. We tested a total of 5 stool ova and parasite excavations and none had positive findings. According to the Centers for Disease Control and Prevention and other tropical disease information sources,<sup>8</sup> eggs should be available for detection on a simple smear (1 to 2 mg of fecal material). As eggs can be passed intermittently or in small amounts, specificity is enhanced by performing multiple examinations by using the formalin–ethyl acetate technique to increase the concentration, or by using the Kato-Katz technique (20 to 50 mg of fecal material) or the Ritchie technique (suspension of approximately 2 g of stool in 10 mL of water at 45°C followed by filtration, centrifugation, and microscopic evaluation).<sup>9</sup> It is also suspected that egg excretion occurs with a circadian rhythm peaking at noon, so samples should be collected between 10:00 AM and 2:00 PM.<sup>9</sup> As in this case, if eggs cannot be identified on stool tests, a rectal biopsy should be performed with multiple samples taken. In this case, the histologic sample provided the definite diagnosis.

### Conclusion

This case was challenging, with differential diagnoses of several diseases including infectious bacterial diarrhea, schistosomiasis, and malaria. Several discrepancies in the workup and history made this case difficult to diagnose and treat. This case also highlights the global

health concerns of how quickly diseases can be transmitted from country to country, and points to how sound global public health structures can limit or eradicate disease using simple patient education to avoid contaminated water and use proper hygiene practices. 

**Dr Greer** is a family physician with Clinica Family Health Services in Boulder, Colo.

**Dr Singh** is a family physician with the Family Practice Center in Newport, Tenn. **Dr Blake** is Professor and Chair in the Department of Family Medicine in the Graduate School of Medicine at the University of Tennessee in Knoxville. **Dr Stockton** is Professor in the Department of Family Medicine in the Graduate School of Medicine at the University of Tennessee.

**Competing interests**

None declared

**Correspondence**

**Dr M. David Stockton**; e-mail [dstockto@utmck.edu](mailto:dstockto@utmck.edu)

**References**

1. World Health Organization. *Schistosomiasis*. Geneva, Switz: World Health Organization; 2017. Available from: [www.who.int/mediacentre/factsheets/fs115/en](http://www.who.int/mediacentre/factsheets/fs115/en). Accessed 2018 Jan 4.
2. Montgomery S. Schistosomiasis. Chapter 3: infectious diseases related to travel. In: Centers for Disease Control and Prevention. *CDC yellow book 2018: health information for international travel*. New York, NY: Oxford University Press; 2017. Available from: <https://wwwnc.cdc.gov/travel/yellowbook/2018/infectious-diseases-related-to-travel/schistosomiasis>. Accessed 2018 Jan 16.
3. Clerinx J, Soentjens P. *Epidemiology, pathogenesis, and clinical manifestations of schistosomiasis*. Waltham, MA: UpToDate; 2017. Available from: [www.uptodate.com/contents/epidemiology-pathogenesis-and-clinical-manifestations-of-schistosomiasis](http://www.uptodate.com/contents/epidemiology-pathogenesis-and-clinical-manifestations-of-schistosomiasis). Accessed 2018 Jan 4.
4. Global Health—Division of Parasitic Diseases. *Parasites—schistosomiasis. Biology*. Atlanta, GA: Centers for Disease Control and Prevention; 2012. Available from: [www.cdc.gov/parasites/schistosomiasis/biology.html](http://www.cdc.gov/parasites/schistosomiasis/biology.html). Accessed 2014 Jan 1.
5. Gryseels B. Schistosomiasis. *Infect Dis Clin North Am* 2012;26(2):383-97.
6. Global Health—Division of Parasitic Diseases. *Parasites—schistosomiasis. Resources for health professionals*. Atlanta, GA: Centers for Disease Control and Prevention; 2012. Available from: [www.cdc.gov/parasites/schistosomiasis/health\\_professionals/index.html](http://www.cdc.gov/parasites/schistosomiasis/health_professionals/index.html). Accessed 2018 Jan 5.
7. Petersen A, Held N, Heide L; Difam-EPN Minilab Survey Group. Surveillance for falsified and substandard medicines in Africa and Asia by local organizations using the low-cost GPHF Minilab. *PLoS One* 2017;12(9):e0184165.
8. Global Health—Division of Parasitic Diseases and Malaria. *Schistosomiasis infection. Laboratory diagnosis*. Atlanta, GA: Centers for Disease Control and Prevention; 2013. Available from: [www.cdc.gov/dpdx/schistosomiasis/dx.html](http://www.cdc.gov/dpdx/schistosomiasis/dx.html). Accessed 2018 Jan 5.
9. Soentjens P, Clerinx J. *Diagnosis of schistosomiasis*. Waltham, MA: UpToDate; 2017. Available from: [www.uptodate.com/contents/diagnosis-of-schistosomiasis](http://www.uptodate.com/contents/diagnosis-of-schistosomiasis). Accessed 2018 Jan 4.

This article has been peer reviewed.

Cet article a fait l'objet d'une révision par des pairs.

*Can Fam Physician* 2018;64:123-6