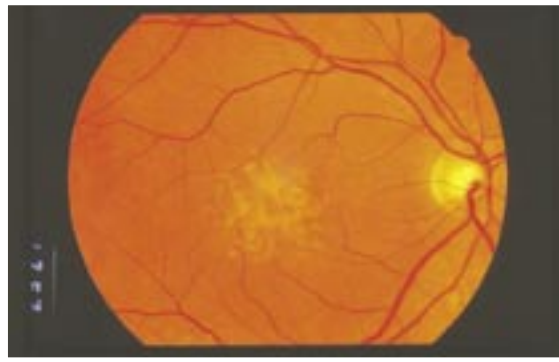


# Ophthaproblem

Sanjay Sharma, MD, MSC, MBA, FRCSC   Gaurav K. Shah, MD

.....



A 64-year-old man presents complaining of mild visual changes in his right eye. His visual acuity is recorded at 6/9 in this eye. He is otherwise healthy.

**The patient should consider having which of the following?**

1. Vitamin supplementation
2. Thermal laser photocoagulation
3. Photodynamic therapy with verteporfin for injection
4. No treatment

*Answer on page 477*

.....

**Dr Sharma** is an Associate Professor in the Department of Ophthalmology and an Assistant Professor in the Department of Epidemiology at Queen's University in Kingston, Ont, and is Director of the Cost-Effective Ocular Health Policy Unit at the Hotel Dieu Hospital. **Dr Shah** is an Assistant Professor of Ophthalmology at Washington University and a retinal specialist at the Barnes Eye Institute in St Louis, Mo.