Answer to Dermacase *continued from* ***page 1415***

3. Focal epithelial hyperplasia

First described in 1965, focal epithelial hyperplasia (FEH), also known as *Heck disease,* is a benign, proliferative cutaneous disorder that commonly affects the oral mucosa of children.[1-4] Its prevalence is highest in Native and Inuit populations and it predominantly affects women and girls. Focal epithelial hyperplasia is clinically characterized by multiple asymptomatic, soft, mucosa-coloured papules or nodules (**Figure 1**), sometimes with lobulated or verrucose surfaces, on the lower lip, upper lip, buccal mucosa, and tongue (in order of decreasing frequency).[1-4] Results of histology usually reveal focal parakeratosis, focal koilocytosis, and sparse perivascular lymphocytic infiltration of the superficial layer of the lamina propria.[1-4] Cellular atypia and mitoses are typically absent. Results of a biopsy taken from the inner lip of our patient revealed similar characteristic findings.

Figure 1. The soft, mucosa-coloured papules characteristic of focal epithelial hyperplasia on the upper aspect of the labial mucous membrane in a 13-year-old boy

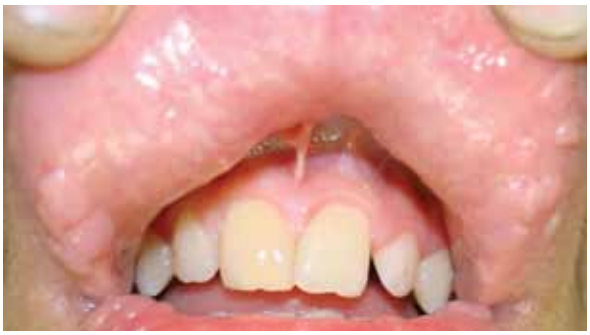

Although several factors, including genetics, malnutrition, and poor personal hygiene, might contribute to the development of FEH, the main predisposing factor is thought to be human papillomavirus infection, particularly types 13 and 32, which have frequently been detected in FEH lesions by polymerase chain reaction or in situ hybridization.[1-4]

Differential diagnosis

Clinical differential diagnosis of FEH includes irritation fibromas, mucosal neuromas, and white sponge nevus.[5-7] Irritation fibromas usually present as soft, mucosa-coloured papules along the buccal occlusal line, as they usually arise secondary to irritation or masticatory trauma.[5] Mucosal neuromas usually present in early childhood as multiple pink, pediculated papules or nodules on the mucosa of the lips and tongue.[6] They often represent the earliest manifestation of multiple endocrine neoplasia syndrome type 2B, an autosomal dominant disorder also characterized, with varying frequency, by medullary carcinoma of the thyroid, pheochromocytoma, gastrointestinal ganglioneuromas, marfanoid features, and skeletal abnormalities.[6] White sponge nevus is a rare autosomal dominant disorder caused by mutations in the keratin-13 gene.[7] Clinically, it is characterized by bilateral white, soft, thick, spongy plaques, usually of the buccal mucosa. In difficult cases, histology might be required to make a distinction between FEH and white sponge nevus.[7]

Management

The clinical course of FEH is variable. Although some lesions resolve spontaneously over several months, others might persist indefinitely. In such cases, many possible treatments (including topical agents such as interferon or imiquimod, cryotherapy, electrocauterization, surgical excision, laser ablation, and systemic retinoic acid) have been tried with varying results.[1-4] Our patient elected to have no treatment and his lesions resolved spontaneously within 3 months.

Ms Abdullah was a registered nurse in the Department of Nursing at the American University of Beirut in Lebanon. **Dr Abbas** is Assistant Professor of Clinical Dermatology in the Department of Dermatology at the American University of Beirut.

Competing interests
None declared

References

1. Archard HO, Heck JW, Stanley HR. Focal epithelial hyperplasia: an unusual oral mucosal lesion found in Indian children. *Oral Surg Oral Med Oral Pathol* 1965;20:210-2.
2. Yasar S, Mansur AT, Serdar ZA, Goktay F, Aslan C. Treatment of focal epithelial hyperplasia with topical imiquimod: report of three cases. *Pediatr Dermatol* 2009;26(4):465-8.
3. Bennett LK, Hinshaw M. Heck's disease: diagnosis and susceptibility. *Pediatr Dermatol* 2009;26(1):87-9.
4. Steinhoff M, Metze D, Stockfleth E, Luger TA. Successful topical treatment of focal epithelial hyperplasia (Heck's disease) with interferon-beta. *Br J Dermatol* 2001;144(5):1067-9.
5. Gonsalves WC, Chi AC, Neville BW. Common oral lesions: part II. Masses and neoplasia. *Am Fam Physician* 2007;75(4):509-12.
6. Cangiarella J, Jagirdar J, Adelman H, Budzilovich G, Greco MA. Mucosal neuromas and plexiform neurofibromas: an immunocytochemical study. *Pediatr Pathol* 1993;13(3):281-8.
7. Richard G, de Laurenzi V, Didona B, Bale SJ, Compton JG. Keratin 13 point mutation underlies the hereditary mucosal epithelial disorder white sponge nevus. *Nat Genet* 1995;11(4):453-5.