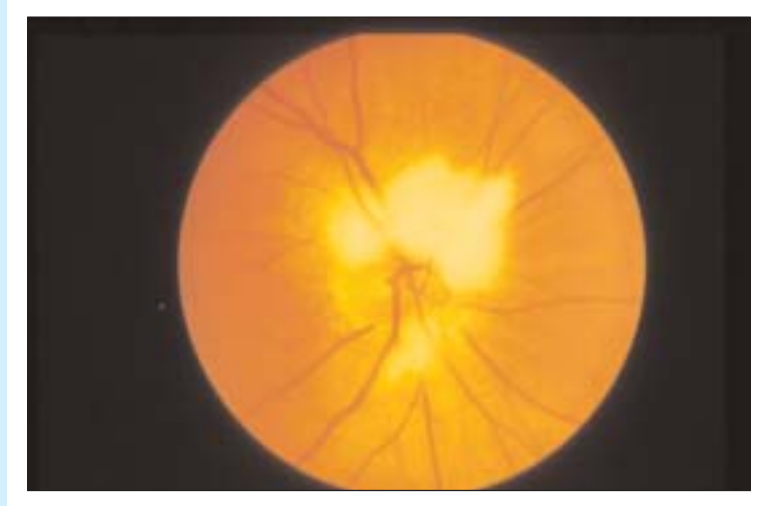



# Ophthalmopproblem

Stephanie Baxter, MD Sanjay Sharma, MD, MSC, MBA, FRCSC



A healthy 56-year-old woman came to her family doctor for troublesome migraine headaches. Fundoscopic findings were normal for her left eye, but her right eye showed some abnormalities.

**The appearance of the optic disk is compatible with the patient's having which of the following?**

1. Myelinated retinal nerve fibre layer
2. Papilledema
3. Pseudopapilledema
4. Astrocytic hamartoma

Answer on page 1741

**Dr Baxter** is a third-year resident in the Department of Ophthalmology at Queen's University in Kingston, Ont.

**Dr Sharma** is an Associate Professor in the Department of Ophthalmology and an Assistant Professor in the Department of Epidemiology at Queen's University.