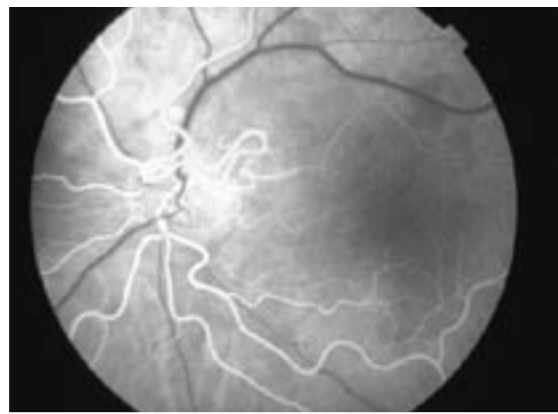
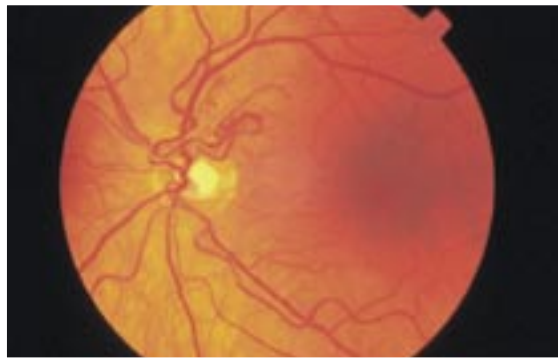


# Ophthalmopblem

Karim Punja, MD Sanjay Sharma, MD, MSC, MBA, FRCSC

.....



A 41-year-old man presents with difficulties reading close up. He is otherwise healthy and has no other symptoms.

**The appearance of this patient's eye is compatible with his having which of the following?**

1. Diabetic retinopathy
2. Prepapillary vascular loops
3. Cataract
4. Solar maculopathy

*Answer on page 50*

.....  
**Dr Punja** is Chief Resident in the Department of Ophthalmology at Queen's University in Kingston, Ont. **Dr Sharma** is an Associate Professor in the Department of Ophthalmology and an Assistant Professor in the Department of Epidemiology at Queen's University.