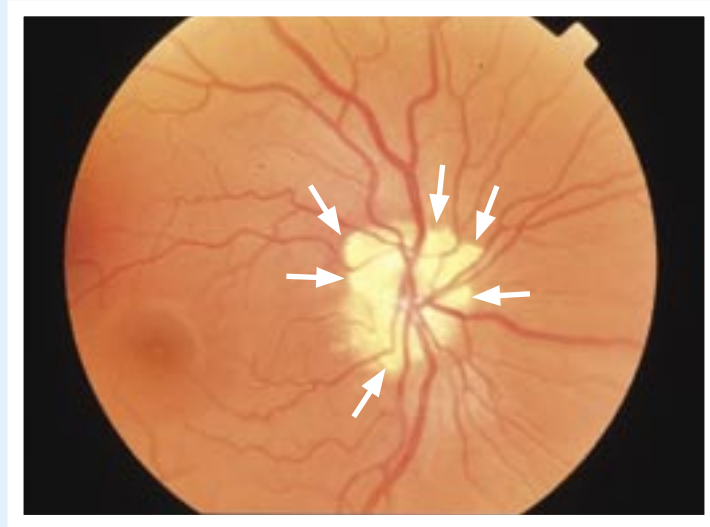


Ophthalmoprobem

Stephanie Baxter, MD Sanjay Sharma, MD, MSC, MBA, FRCSC

.....



A healthy 23-year-old woman came to her family doctor complaining of headaches. Funduscopy examination revealed an abnormality in both her eyes.

The clinical history and the appearance of her optic disks is compatible with the patient's having which of the following?

1. Optic atrophy
2. Glaucoma
3. Papilledema
4. Pseudopapilledema

Answer on page 889

.....

Dr Baxter is a fourth-year resident in the Department of Ophthalmology at Queen's University in Kingston, Ont.

Dr Sharma is an Associate Professor in the Department of Ophthalmology and an Assistant Professor in the Department of Epidemiology at Queen's University.