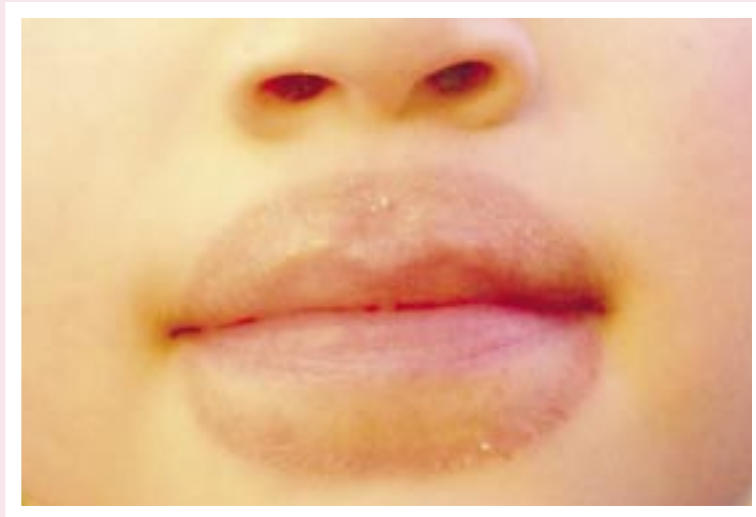


# Dermacase

Christopher J. Watt, MD H. Chih-ho Hong, MD

.....



## CAN YOU IDENTIFY THIS CONDITION?

A healthy 7-year-old girl presented with recurrent dermatitis around her mouth. The dermatitis worsened during the winter. No previous treatment had been initiated. There was no associated pain and only slight pruritus.

### The most likely diagnosis is:

1. Perioral dermatitis
2. Iron deficiency
3. Primary herpes simplex gingivostomatitis
4. Lip licker's dermatitis

*Answer on page 1059*

.....  
*Dr Watt is in private practice in Vancouver, BC. Dr Hong is a senior resident in dermatology at the University of British Columbia in Vancouver.*