

## Top 10 differential diagnoses in family medicine: Vertigo and dizziness

David Ponka MD Michael Kirlew MD

### 8. VERTIGO/DIZZINESS

**First, clarify what the patient means by "dizziness". True vertigo must be differentiated from lightheadedness or ocular symptoms, such as diplopia.**

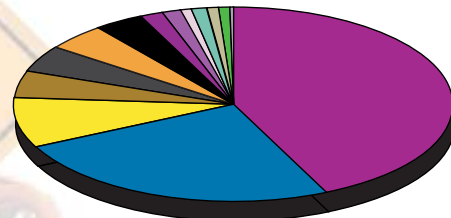
Vertigo, a subjective impression of movement of self or of one's environment, has a long differential diagnosis. It is convenient to attempt to classify vertigo into central versus peripheral causes. The latter are usually more benign (with the exception of acoustic neuroma), but paradoxically produce more intense symptoms, including severe, episodic nausea or vomiting. Causes of peripheral vertigo also tend to have associated hearing loss or tinnitus.

Constant nystagmus or vertical nystagmus usually points to a more serious disorder, as does persistent ataxia or other neurological deficits.

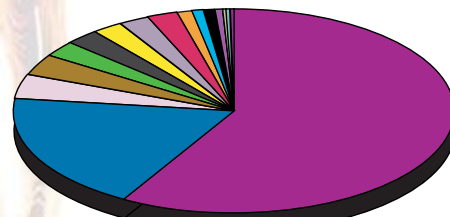
The most common causes of vertigo in the generalist's office include:

- viral labyrinthitis;
- benign positional vertigo;
- Eustachian tube dysfunction (often with serous OM);
- Meniere's disease; and
- Vertebrobasilar insufficiency (in the elderly with vasculopathy).

**Ddx**



Under 45



45 and Over

	AGE	
	Under 45	45 and Over
Vertigo NYD	43.90 %	57.80 %
Anxiety	8.50	2.20
Postural Hypotension	4.50	2.40
HTN	1.00	4.00
Fatigue	4.40	1.20
Medication Side Effect	0.80	2.50
Cervical Disease	4.60	3.10
Iron Deficiency Anemia	3.90	0.80
CVA	0.09	2.20
TIA	0.00	2.20
URI	1.30	0.40
Concussion	1.60	0.20
Atrial Fibrillation	0.00	0.90
Sinusitis	1.00	0.30
Tension Headache	1.00	0.30
Other	25.10	18.40

CVA—cerebrovascular accident; HTN—hypertension; NYD—not yet diagnosed; OM—otitis media; TIA—transient ischemic attack; URI—upper respiratory infection.

For a pdf of the Top Ten Differential Diagnoses in Family Medicine pamphlet or to access the slide show on-line, go to <http://www.familymedicine.uottawa.ca/eng/TopTenDifferentialDiagnosisInPrimaryCare.aspx>.

Dr Ponka is an Assistant Professor and Dr Kirlew is a second-year resident in the Department of Family Medicine at the University of Ottawa in Ontario.

**Correspondence to:** Dr David Ponka, Assistant Professor, Department of Family Medicine, University of Ottawa; e-mail [dponka@uottawa.ca](mailto:dponka@uottawa.ca)