

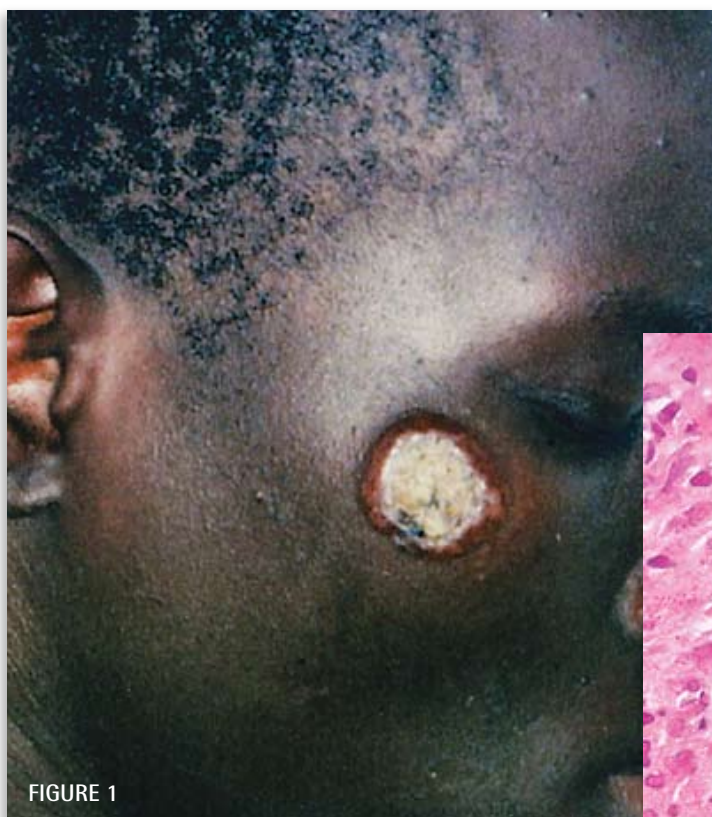

FIGURE 1

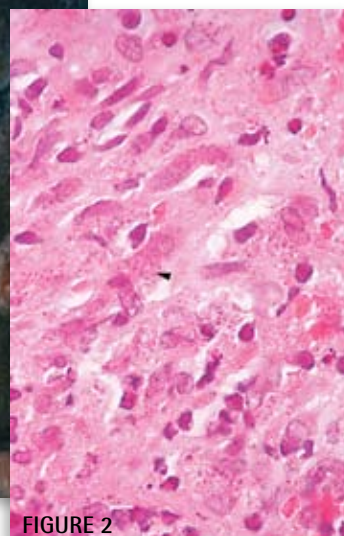


FIGURE 2

Can you identify this condition?

Chau Nguyen MD FRCPC

A 21-year-old man from Sudan presented with a large facial mass. During the 3 months after his arrival in Canada, it had gradually grown to a roundish raised lesion 3 cm in diameter (**Figure 1**). Although there was local pain, there was no discharge, fever, or weight loss. No local lymphadenopathy or hepatosplenomegaly was found. A biopsy of the lesion showed many tiny roundish and basophilic structures within macrophages (**Figure 2**).

The most likely diagnosis is

1. Blastomycosis
2. Cutaneous leishmaniasis
3. Tuberculosis
4. Squamous cell carcinoma

Answer on page 1317