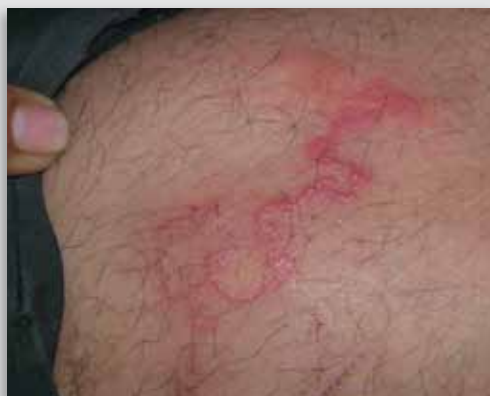

Dermacase



Can you identify this condition?

Sudip Kumar Ghosh MD DNB D.DERMAT
Debabrata Bandyopadhyay MD

A 40-year-old man presents with an advancing, twisting, winding, reddish streak on his left thigh of 7 days' duration. It is associated with mild itching.

The most likely diagnosis is

1. Cutaneous larva migrans
2. Allergic contact dermatitis
3. Erythema annulare centrifugum
4. Acute lymphangitis
5. Blister beetle dermatitis

Answer on page 491

Ophthaprobblem

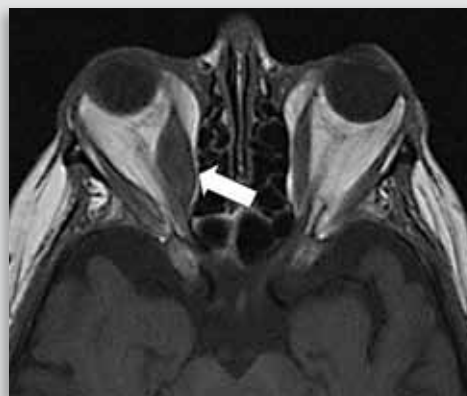


Image courtesy of Dr Eugene Yu

Can you identify this condition?

Malcolm Gooi Mark O. Baerlocher MD
Harmeet S. Gill MD Jason Noble MD

A 42-year-old female smoker presents to your office complaining of binocular vertical diplopia. Clinical examination reveals normal vision, pupil reactivity, and visual fields. There is no relative afferent pupillary defect; however, there is evidence of proptosis of the right eye, with restricted elevation of that eye during upward gaze. Magnetic resonance imaging is shown above.

The most likely diagnosis is

1. Myasthenia gravis
2. Horner syndrome
3. Thyroid orbitopathy
4. Preseptal cellulitis

Answer on page 492