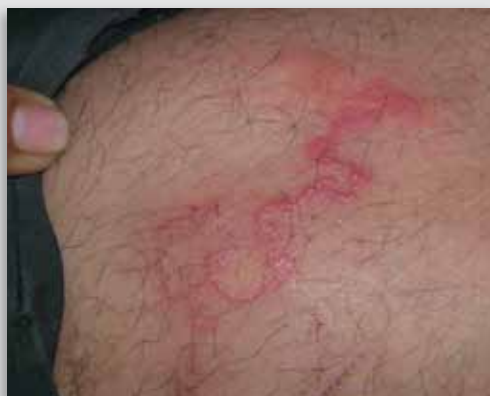

## Dermacase



### Can you identify this condition?

Sudip Kumar Ghosh MD DNB D.DERMAT  
Debabrata Bandyopadhyay MD

**A** 40-year-old man presents with an advancing, twisting, winding, reddish streak on his left thigh of 7 days' duration. It is associated with mild itching.

#### The most likely diagnosis is

1. Cutaneous larva migrans
2. Allergic contact dermatitis
3. Erythema annulare centrifugum
4. Acute lymphangitis
5. Blister beetle dermatitis

*Answer on page 491*

## Ophthalmproblem

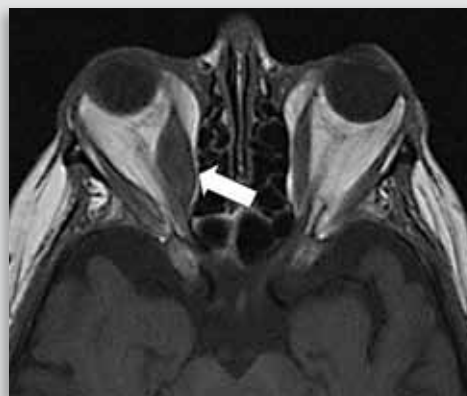


Image courtesy of Dr Eugene Yu

### Can you identify this condition?

Malcolm Gooi Mark O. Baerlocher MD  
Harmeet S. Gill MD Jason Noble MD

**A** 42-year-old female smoker presents to your office complaining of binocular vertical diplopia. Clinical examination reveals normal vision, pupil reactivity, and visual fields. There is no relative afferent pupillary defect; however, there is evidence of proptosis of the right eye, with restricted elevation of that eye during upward gaze. Magnetic resonance imaging is shown above.

#### The most likely diagnosis is

1. Myasthenia gravis
2. Horner syndrome
3. Thyroid orbitopathy
4. Preseptal cellulitis

*Answer on page 492*