

## Challenges to diagnosing colorectal cancer during pregnancy

Mohammad Yaghoobi MD MSc Gideon Koren MD FRCPC FACMT Irena Nulman MD FRCPC

### ABSTRACT

**QUESTION** My patient is 13 weeks pregnant and has experienced rectal bleeding and vomiting. Should I send her for a colonoscopy to rule out colorectal malignancies or should I wait until after delivery?

**ANSWER** The data on colorectal cancer in pregnancy are scarce; however, as the presenting features of colorectal cancer overlap with those of pregnancy itself, there is a risk of development of advanced disease, with poorer prognosis at diagnosis. Therefore, it is strongly recommended that this patient, who is in her second trimester, undergo at least a flexible sigmoidoscopy, which is presumed safe during pregnancy, with or without a liver ultrasound and carcinoembryonic antigen detection based on pretest probability according to her other risk factors.

### RÉSUMÉ

**QUESTION** Une de mes patientes, enceinte de 13 semaines, a connu un épisode de saignements rectaux et de vomissements. Devrais-je lui faire passer une colonoscopie pour écarter la possibilité d'un cancer ou encore attendre après l'accouchement?

**RÉPONSE** Les données sur le cancer colorectal durant la grossesse sont rares; cependant, étant donné que les caractéristiques présentes dans un cancer colorectal chevauchent celles de la grossesse elle-même, il y a un risque de développement d'une maladie à un stade avancé et de moins bon pronostic au moment du diagnostic. Par conséquent, il est fortement recommandé que cette patiente, qui en est à son deuxième trimestre, subisse au moins une sigmoïdoscopie flexible, présumée sans risque durant la grossesse, avec ou sans échographie du foie et dépistage de l'antigène carcinoembryonique, en se fondant sur la probabilité avant l'analyse en fonction de ses autres facteurs de risque.

Ofentimes the presenting symptoms of serious conditions overlap with common symptoms of pregnancy, such as nausea and vomiting, pruritus, or hemorrhoids. It is important not to miss critical diagnoses that might put both mother and unborn child at serious health risk. In this Motherisk Update, we focus on colorectal cancer. The risk of this condition occurring during pregnancy has increased, as more women are postponing pregnancy until later in life.

### Epidemiology

Cruveilhier reported the first case of rectal carcinoma in pregnancy in 1842.<sup>1</sup> Cancer incidence has been estimated at approximately 1 in every 1000 pregnancies.<sup>2</sup> Colorectal cancer is the seventh most common type of cancer diagnosed in pregnancy, with an estimated incidence of 1 in 13000 pregnancies in 1992.<sup>3</sup> This would translate to 30 new cases a year in Canada. To our knowledge there are no more recent epidemiologic data on the incidence of colorectal cancer in pregnancy. The mean age of diagnosis in 1 large review was 31 years.<sup>4</sup>

Diagnosis of cancer during pregnancy can be a potentially devastating situation associated with serious emotional and physical stress for the pregnant woman and her family.<sup>5</sup> The decision about abortion as a therapeutic choice could increase this burden even further. Early diagnosis and treatment are important in colorectal cancer during pregnancy.

### Clinical features

Common presenting symptoms of colorectal cancer include abdominal pain, constipation, vomiting, anemia, and rectal bleeding; most of these symptoms might be attributed to pregnancy itself and be overlooked.<sup>6</sup> Rectal bleeding can also be attributed to hemorrhoids, which are common in pregnant women. For this reason most cases of colorectal cancer are diagnosed later in pregnancy when more widespread metastasis has occurred.<sup>3</sup>

Contrary to the general population, 86% of colorectal tumours found during pregnancy occur below the peritoneal reflection.<sup>4</sup> These tumours are detectable by flexible sigmoidoscopy without the need for sedation and radiation exposure. Cases of familial adenomatous

polyposis have also been reported to be first diagnosed during pregnancies.<sup>7</sup>

### Diagnosis

The American Society of Gastrointestinal Endoscopy guidelines indicate that in situations in which therapeutic intervention is necessary, endoscopy offers a relatively safe alternative to radiologic or surgical intervention.<sup>8</sup> Endoscopy during pregnancy should be done only when there is a strong indication and should be postponed to the second trimester whenever possible. Maternal oversedation, with resulting hypoventilation or hypotension, or maternal positioning that might lead to the compression of the inferior vena cava by the uterus can potentially lead to decreased uterine blood flow and fetal hypoxia. Other potential risks to the fetus include teratogenesis (from sedative medication) and premature birth.<sup>8</sup>

Once diagnosed, the evaluation of pregnant patients with colorectal carcinoma is similar to the evaluation of nonpregnant patients.<sup>9</sup> Examination requires the following: complete colonoscopy to screen for synchronous lesions; an endoluminal ultrasonograph to confirm staging of rectal lesions; monitoring of serum carcinoembryonic antigen levels for follow-up purposes; and a liver ultrasound for detection of metastatic liver disease. Magnetic resonance imaging is an appropriate substitute for computed tomography in staging when needed.<sup>10</sup> When advanced rectal cancer is diagnosed in the latter stages of pregnancy, careful assessment of the tumour site and cancer stage is made to ensure that the tumour will not obstruct a normal labour and vaginal delivery.<sup>11</sup>

### Fetal risk

There are no reports of adverse fetal outcomes due to the malignancy itself, even in widespread metastatic disease.<sup>12</sup> Metastasis to the placenta was reported once in maternal colorectal malignancy.<sup>13</sup> Although a complete evaluation of the placenta is recommended, there is no evidence to support periodic follow-up of the baby. There is a 78% rate of fetal survival in pregnancies complicated by colorectal carcinoma.<sup>6,14</sup>

Maternal colorectal malignancy might affect pregnancy outcome. Only 25 of 32 pregnancies complicated by colonic tumours resulted in healthy live-born infants in 1 study.<sup>3</sup> Deaths were due to stillbirth, prematurity, or termination.

In the case of this patient, the fetus was not involved and was normal; therefore, there was no fetal indication for a therapeutic abortion.

### Treatment

When diagnosis of colorectal cancer is made during pregnancy, multidisciplinary involvement of the obstetrician, perinatologist, colorectal surgeon, and radiation and medical oncologists is essential to achieving the

goal of early delivery that allows for the earliest treatment of the patient's cancer.<sup>14</sup>

Treatment and prognosis by cancer stage are not different from those in the general population. There are several factors to consider when planning management: location of the cancer, gestational age, elective versus emergency presentation, the stage of the tumour, complications of tumour or pregnancy, and the patient's decision.<sup>9</sup> Unfortunately, colon cancer in pregnancy is often diagnosed at an advanced stage when surgical management and adjuvant chemotherapy are barely effective. **Figures 1** and **2** are the proposed guidelines by Walsh and Fazio.<sup>9</sup>

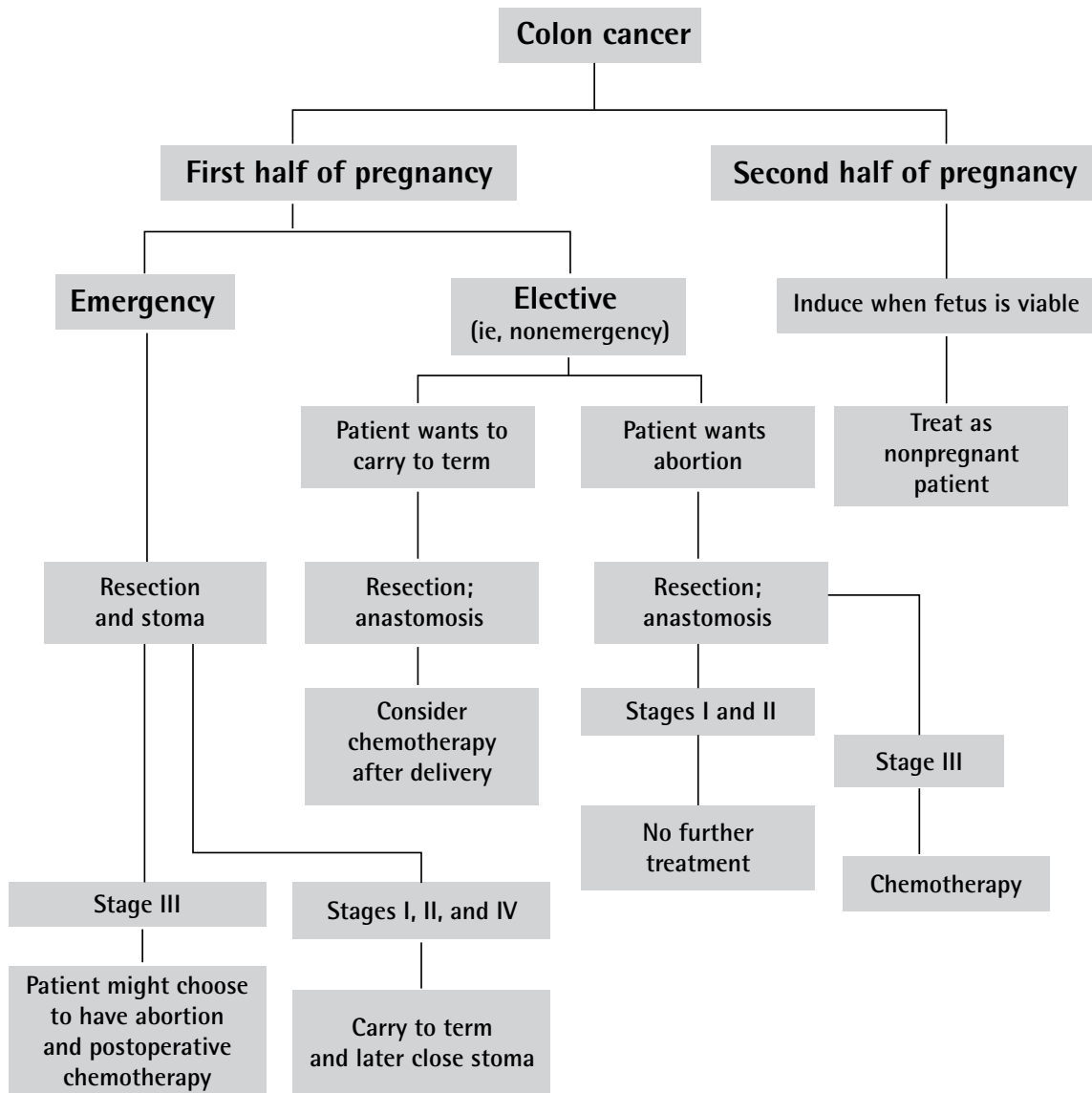Surgery could be performed safely before 20 weeks of gestation when appropriate.<sup>15</sup> After this gestational age it is recommended that surgery be delayed to have a reasonable maturation of the fetus. It has been proposed that colon cancer surgery can be done right after an uncomplicated cesarean section.<sup>9</sup> Intraoperatively, the patient should be placed in the slight left lateral position to prevent uterine compression of the inferior vena cava and left iliac vein. Maternal blood gases should be monitored, as carbon dioxide insufflation can induce maternal hypercapnia, which can lead to fetal hypercapnia, tachycardia, and hypertension.<sup>16</sup>

The mode of delivery is not affected by cancer, with the exception of a cesarean section owing to a distal tumour obstructing the birth canal or anterior rectal wall carcinoma. The placenta should be carefully examined for metastases.<sup>17</sup>

Adjuvant chemotherapy with 5-fluorouracil (5-FU) is suggested for stage III tumours; however, the risk and benefits should be discussed with the patient.<sup>9</sup> The most serious complications occur when the chemotherapy is given from 3 to 12 weeks of gestation.<sup>18</sup> In animal models, this agent is highly teratogenic. In several case reports, 5-FU during the first trimester has been associated with spontaneous abortion as well as normal-term births.<sup>19-23</sup> In one case, a patient who had 5-FU administered in high doses over 5 months of the second and third trimesters gave birth to a healthy but small baby.<sup>24</sup> Moreover, no congenital anomalies or other clinically significant adverse effects were observed in 40 infants whose mothers were treated for breast cancer during the second and third trimesters of pregnancy with intravenous fluorouracil in combination with doxorubicin, cyclophosphamide, and other chemotherapeutic agents.<sup>25-27</sup> Transient cyanosis and jerky movements were reported in a newborn whose mother received 5-FU during the third trimester.<sup>28</sup> There are no reports on the use of 5-FU during lactation. Cisplatin and other platinum-based chemotherapy drugs are also used in colorectal cancer, but they are not recommended during pregnancy or breastfeeding.<sup>29</sup>

Chemotherapy is safer during the second and third trimester of pregnancy, although there is an increase

Figure 1. Management of colon cancer in pregnancy



Adapted from Walsh and Fazio.<sup>9</sup> Used with permission.

in the incidence of intrauterine growth retardation and prematurity.<sup>30</sup> Although a few cancer chemotherapy studies have failed to show adverse effects in treatment in the third trimester, the possible neurocognitive effect of chemotherapy cannot be totally excluded because brain development is not completed during pregnancy or even early in life.<sup>31</sup>

Adjuvant radiotherapy is used in the management of rectal cancer. Radiation therapy to the pelvis is not recommended during pregnancy because of the potential harm to the fetus. Fetal radiation exposure should be measured by a medical physicist in any radiation during

pregnancy.<sup>32</sup> Pelvic radiation after delivery can be considered, but should be discussed with the patient, as it might end in infertility.<sup>33</sup>

### Conclusion


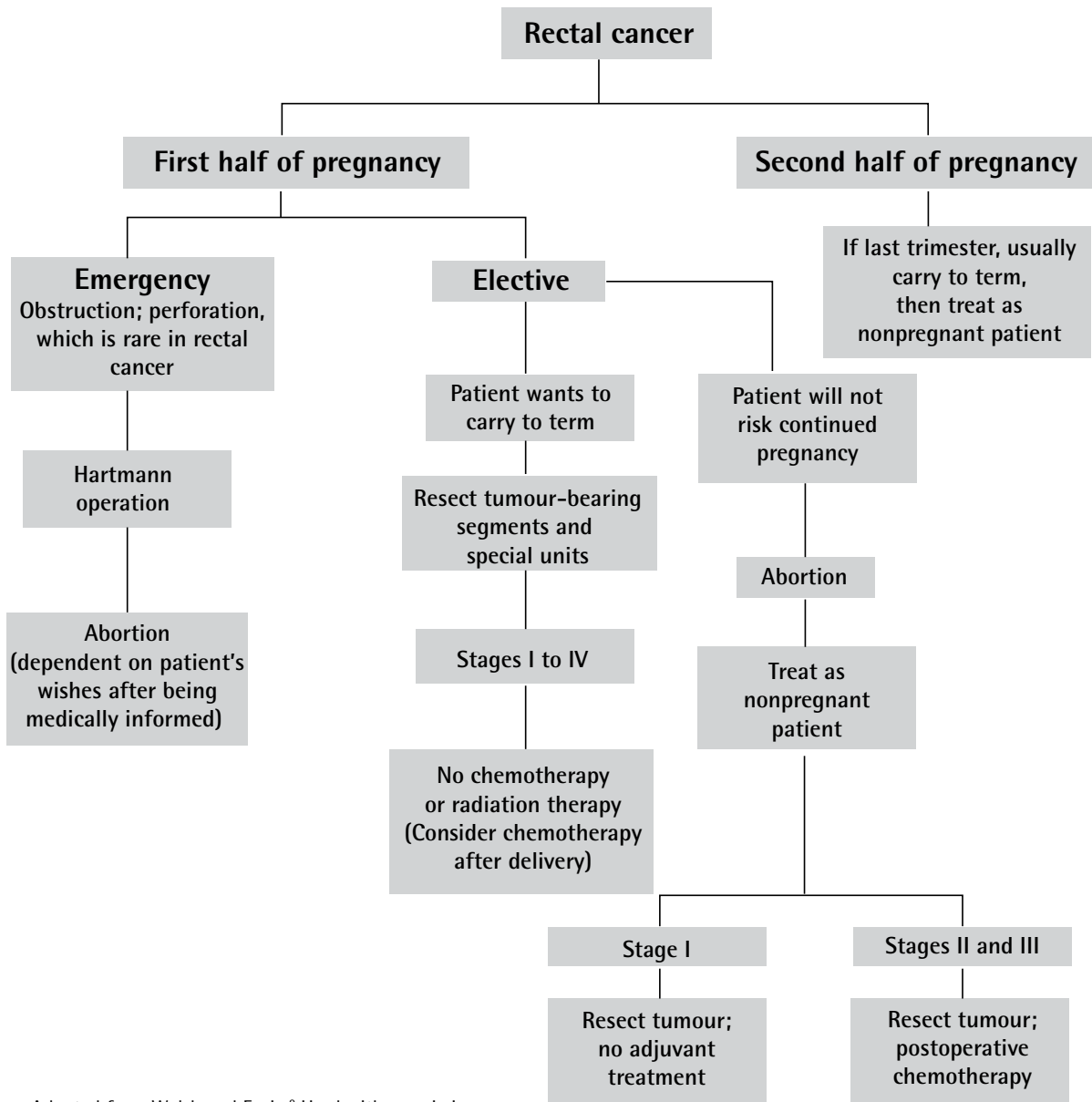
Colorectal carcinoma is a rare but devastating event during pregnancy. Because presentation can overlap with the signs and symptoms of pregnancy, diagnoses are often a challenge. Principles of treatment of colorectal cancer during pregnancy are not different from those in the general population, but special care regarding fetal safety should be considered. 

Figure 2. Management of rectal cancer in pregnancy



Adapted from Walsh and Fazio.<sup>9</sup> Used with permission.

**Competing interests**

None declared

**References**

1. Cruveilhier JJ. *Anatomie pathologique du corps humaine*. Volume 2. Paris, France: JB Baillière; 1829. p. 7-10.
2. Donegan WL. Cancer and pregnancy. *CA Cancer J Clin* 1983;33(4):194-214.
3. Woods JB, Martin JN Jr, Ingram FH, Odom CD, Scott-Conner CE, Rhodes RS. Pregnancy complicated by carcinoma of the colon above the rectum. *Am J Perinatol* 1992;9(2):102-10.
4. Bernstein MA, Madoff RD, Caushaj PF. Colon and rectal cancer in pregnancy. *Dis Colon Rectum* 1993;36(2):172-8.
5. Oduncu FS, Kimmig R, Hepp H, Emmerich B. Cancer in pregnancy: maternal fetal conflict. *J Cancer Res Clin Oncol* 2003;129(3):133-46. Epub 2003 Mar 18.
6. Vitoratos N, Salamalekis E, Makrakis E, Creatsas G. Sigmoid colon cancer during pregnancy. *Eur J Obstet Gynecol Reprod Biol* 2002;104(1):70-2.
7. Lolis ED, Likoudis P, Voiniadis P, Hassiakos D, Samanides L. Synchronous rectal and colon cancer caused by familial polyposis coli during pregnancy. *J Obstet Gynaecol Res* 2007;33(2):199-202.
8. Qureshi WA, Rajan E, Adler DG, Davila RE, Hirota WK, Jacobson BC, et al. ASGE guideline: guidelines for endoscopy in pregnant and lactating women. *Gastrointest Endosc* 2005;61(3):357-62.
9. Walsh C, Fazio VW. Cancer of the colon, rectum, and anus during pregnancy. The surgeon's perspective. *Gastroenterol Clin North Am* 1998;27(1):257-67.
10. Moran BJ, Yano H, Al Zahir N, Farquharson M. Conflicting priorities in surgical intervention for cancer in pregnancy. *Lancet Oncol* 2007;8(6):536-44.
11. Lamerz R, Ruider H. Significance of CEA determinations in patients with cancer of the colon-rectum and the mammary gland in comparison to physiological states in connection with pregnancy. *Bull Cancer* 1976;63(4):575-86.
12. Heres P, Wiltink J, Cuesta MA, Burger CW, van Groeningen CJ, Meijer S. Colon carcinoma during pregnancy: a lethal coincidence. *Eur J Obstet Gynecol Reprod Biol* 1993;48(2):149-52.
13. Rothman LA, Cohen CJ, Astarloa J. Placental and fetal involvement by maternal malignancy: a report of rectal carcinoma and review of the literature. *Am J Obstet Gynecol* 1973;116(7):1023-34.
14. Kitoh T, Nishimura S, Fukuda S, Hirabuki S, Kaganoi J, Tokunaga Y, et al. The incidence of colorectal cancer during pregnancy in Japan: report of two cases and review of Japanese cases. *Am J Perinatol* 1998;15(3):165-71.

15. Cohen-Kerem R, Railton C, Oren D, Lishner M, Koren G. Pregnancy outcome following non-obstetric surgical intervention. *Am J Surg* 2005;190(3):467-73.
16. Schirmer B, Kouretas PC. Gallstone pancreatitis. In: Cameron JL, editor. *Current surgical therapy*. 7th ed. Philadelphia, PA: Mosby; 2001. p. 528-33.
17. Dildy DA 3rd, Moise KJ Jr, Carpenter RJ Jr, Klima T. Maternal malignancy metastatic to the products of conception: a review. *Obstet Gynecol Surv* 1989;44(7):535-40.
18. Pentheroudakis G, Pavlidis N, Castiglione M; ESMO Guidelines Working Group. Cancer, fertility and pregnancy: ESMO clinical recommendations for diagnosis, treatment and follow-up. *Ann Oncol* 2008;19(Suppl 2):ii108-9.
19. Giannakopoulou C, Manoura A, Hatzidaki E, Korakaki E, Froudarakis G, Koumandakis E. Multimodal cancer chemotherapy during the first and second trimester of pregnancy: a case report. *Eur J Obstet Gynecol Reprod Biol* 2000;91(1):95-7.
20. Andreadis C, Charalampidou M, Diamantopoulos N, Chouchos N, Mouratidou D. Combined chemotherapy and radiotherapy during conception and first two trimesters of gestation in a woman with metastatic breast cancer. *Gynecol Oncol* 2004;95(1):252-5. Erratum in: *Gynecol Oncol* 2005;96(1):267.
21. Zemlicks D, Lishner M, Degendorfer P, Panzarella T, Sutcliffe SB, Koren G. Fetal outcome after in utero exposure to cancer chemotherapy. *Arch Intern Med* 1992;152(3):573-6.
22. Kopelman JN, Miyazawa K. Inadvertent 5-fluorouracil treatment in early pregnancy: a report of three cases. *Reprod Toxicol* 1990;4(3):233-5.
23. Odom LD, Plouffe L Jr, Butler WJ. 5-Fluorouracil during the period of conception: report on two cases. *Am J Obstet Gynecol* 1990;163(1 Pt 1):76-7.
24. Dreicer R, Love RR. High total dose 5-fluorouracil treatment during pregnancy. *Wis Med J* 1991;90(10):582-3.
25. Berry DL, Theriault RL, Holmes FA, Parisi VM, Booser DJ, Singletary SE, et al. Management of breast cancer during pregnancy using a standardized protocol. *J Clin Oncol* 1999;17(3):855-61.
26. Ring AE, Smith IE, Jones A, Shannon C, Galani E, Ellis PA. Chemotherapy for breast cancer during pregnancy: an 18-year experience from five London teaching hospitals. *J Clin Oncol* 2005;23(18):4192-7.
27. Mathelin C, Annane K, Dufour P, Liegeois P, Bergerat JP. Chemotherapy for breast cancer during pregnancy. *Eur J Obstet Gynecol Reprod Biol* 2005;123(3):260-2. Epub 2005 Jul 15.
28. Stadler HE, Knowles J. Fluorouracil in pregnancy: effect on the neonate. *JAMA* 1971;217(2):214-5.
29. Briggs GG, Freeman RK, Yaffe SJ. *Drugs in pregnancy and lactation*. 5th ed. Baltimore, MD: Williams and Wilkins Co; 1998.
30. Sommers GM, Kao MS. Using chemotherapeutic agents during pregnancy. *Contemp Obstet Gynecol* 1987;30:45-8.
31. Nulman I, Laslo D, Fried S, Uleryk E, Lishner M, Koren G. Neurodevelopment of children exposed in utero to treatment of maternal malignancy. *Br J Cancer* 2001;85(11):1611-8.
32. Pereg D, Koren G, Lishner M. Cancer in pregnancy: gaps, challenges and solutions. *Cancer Treat Rev* 2008;34(4):302-12. Epub 2008 Mar 4.
33. Devita VT, Hellman S, Rosenberg SA. *Cancer. Principles and practice of oncology*. 3rd ed. Philadelphia, PA: JB Lippincott; 1989.

## MOTHERISK

Motherisk questions are prepared by the Motherisk Team at the Hospital for Sick Children in Toronto, Ont. **Dr Yaghoobi** is a resident in the Department of Medicine at the University of Toronto in Ontario and was a member of the Motherisk Program at the time of preparing this update. **Dr Nulman** is Associate Director and **Dr Koren** is Director of the Motherisk Program. **Dr Koren** is supported by the Research Leadership for Better Pharmacotherapy during Pregnancy and Lactation. He holds the Ivey Chair in Molecular Toxicology in the Department of Medicine at the University of Western Ontario in London.

Do you have questions about the effects of drugs, chemicals, radiation, or infections in women who are pregnant or breastfeeding? We invite you to submit them to the Motherisk Program by fax at 416 813-7562; they will be addressed in future Motherisk Updates.

Published Motherisk Updates are available on the *Canadian Family Physician* website ([www.cfp.ca](http://www.cfp.ca)) and also on the Motherisk website ([www.motherisk.org](http://www.motherisk.org)).