


# Genetics

## Huntington disease

Judith Allanson MD Heather Dorman MSc  
 Sean M. Blaine MD Carol Cremin MSc  
 Clare A. Gibbons MS Christina Honeywell MSc  
 Wendy S. Meschino MD Joanne Permaul  
 June C. Carroll MD

**I**nformative genetic testing is currently available to individuals with clinical symptoms suggestive of Huntington disease (HD) and family members of individuals diagnosed with HD. Current research is focused on understanding the cellular basis of HD to inform future treatments and provide the basis for a possible cure.

**Bottom line.** The benefits of genetic testing for HD are limited and mainly relate to the individual's perception of the psychological advantages of knowing whether he or she is predisposed to developing HD. There remains no cure or effective preventive therapy for the disease.

The complete *Gene Messenger—Huntington Disease* by the GenetiKit research team is available on **CFPlus**.<sup>\*</sup> Past Gene Messenger articles can be accessed on-line at [www.cfp.ca](http://www.cfp.ca). On the home page, click on **Collections** in the left-hand menu, then click on **Genetics**. 

**Competing interests**  
 None declared

The **GenetiKit** research team, a group of family physicians, genetic counselors and geneticists, designed the Gene Messenger series to provide practical information to help family physicians and their patients make informed choices about rapidly emerging genetic discoveries. The series is a collection of up-to-date, definitive, short reviews on genetics topics that have made headlines, and offers recommendations regarding referral for genetic services or testing.

**Acknowledgment**  
 Funding was provided by the Canadian Institutes of Health Research.

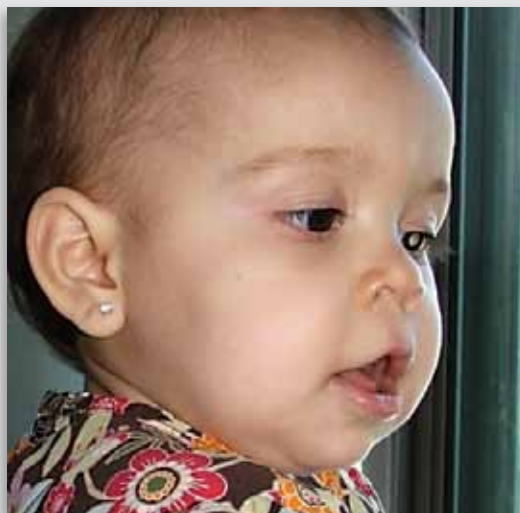### GENE MESSENGER

For more information on genetics topics,  
 see [www.mtsinai.on.ca/FamMedGen/](http://www.mtsinai.on.ca/FamMedGen/)



<sup>\*</sup>The Gene Messenger on Huntington disease is available at [www.cfp.ca](http://www.cfp.ca). Go to the full text of this article on-line, then click on **CFPlus** in the menu at the top right-hand side of the page.

# Ophthalmproblem



## Can you identify this condition?

Nataly Pesin MD Jason Noble MD  
 Brenda L. Gallie MD

**A** 9-month-old female infant is brought to her pediatrician after the mother notices her left eye appeared white in a photograph. The pediatrician cannot elicit a red reflex upon examination of the right eye, indicating leukocoria.

The most likely diagnosis is

1. Cataract
2. Retinoblastoma
3. Coloboma
4. Coats disease
5. All of the above

Answer on page 156