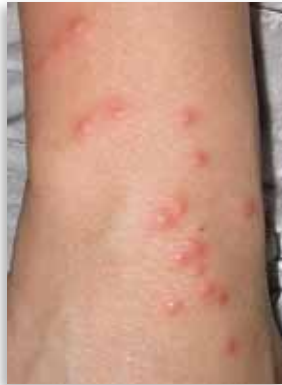

### 3. Bedbugs

The common bedbug, or *Cimex lectularius*, is a nocturnal, bloodsucking insect that feeds on humans and domestic animals.<sup>1</sup> Typically feeding during the hours before dawn, the insects are rarely detected by their sleeping victims. Only after careful inspection of both patients and their homes are the signs of an infestation evident.



Bedbugs have bothered humans for centuries and were traditionally thought to be more prevalent in areas of lower socioeconomic status. Currently, they are found in North America and internationally. One report from rural Gambia identified an incidence of up to 37.5%.<sup>2</sup> Areas of high occupant turnover, such as hotels, hostels, dormitories, and apartments, are more frequently affected than single-occupant dwellings.<sup>1,3</sup>

Improvements in hygiene and the use of DDT following World War II resulted in the bugs having a relatively insignificant domestic presence. More recently, however, the development of bedbug resistance to DDT, pyrethroids, and organophosphates<sup>4</sup>; ready extermination of cockroaches (bedbugs' natural predators); and increased international travel have led to a rise in the incidence of bedbug infestations in affluent and less-affluent areas alike.<sup>5</sup>

### Diagnosis

The key to diagnosing bedbug bites relies on integrating the relatively nonspecific skin findings with a careful clinical history. Clinically, the bites are distributed in exposed areas, including the arms, neck, and face, but on occasion might be generalized. Bites typically occur in clusters or in a linear distribution; lesions that appear 3 in a row are referred to as the "breakfast, lunch, and dinner" sign.<sup>6</sup> Local bite reactions depend on the host's previous sensitivity, and typically manifest as urticarial, erythematous macules and papules, which are worse in the morning and fade throughout the day.<sup>7</sup> Some individuals might even present with vesicles and bullae following bedbug bites.<sup>8</sup>


Patients should conduct careful inspections of their sleeping areas for signs of bedbug presence. These include reddish-brown specks on bed linens; small, brown, 5- to 7-mm long, flat, wingless, oval-shaped insects under mattresses, in crevices, and between floorboards; and piles of reddish-brown, dust-like dung along baseboards.<sup>1</sup> Visual conformation of the bugs helps clinch the diagnosis. Any captured bugs can be sent to the provincial laboratory for speciation.

### Treatment and management

Bedbug bites can cause considerable discomfort, anxiety, and sleep disruption, but they can be treated symptomatically with mid- to high-potency topical steroid creams and cool compresses. Systemic antihistamines (eg, 25 to 50 mg of diphenhydramine taken orally every 4 to 6 hours) can help with urticarial reactions and pruritus, and systemic antibiotics can be prescribed if the bites become secondarily infected. Signs of secondary infection include increased local tenderness, erythema, and lymphadenopathy.<sup>9</sup>

Eradicating bedbugs from the home environment should be attempted. Bedbugs can survive for up to a year between meals, necessitating the use of insecticides in their elimination<sup>1</sup>; professional extermination services should be consulted. Further, a thorough cleaning of the bedroom should take place in order to remove any traces of the bugs and their dung. Clutter should be removed and any crevices in which the bugs might hide or lay eggs should be filled.<sup>1</sup> Steps should be taken to minimize the amount of skin exposed at night, such as wearing long-sleeved nightclothes and applying insect repellent (eg, DEET [diethyltoluamide]) to uncovered skin.<sup>6,10</sup> Patients should be informed that multiple applications of pesticide might be required before the problem is eliminated and that they should continue with symptomatic management of any further lesions. Patients living in apartments or multi-unit housing should notify their landlords or superintendents of the problem.

### Conclusion

Many factors have contributed to the resurgence of this once rare pest, but timely diagnosis of bedbugs can save patients and their families much anxiety and discomfort. If a patient's symptoms are not alleviated after thorough attempts at eliminating the problem or persist in the absence of evidence of the bugs, consultation with a dermatologist is recommended. 

**Dr Hawkins** is a second-year resident at the University of Saskatchewan in Saskatoon. **Dr Barankin** is a dermatologist practising in Toronto, Ont.

#### Competing interests

None declared

#### References

1. Thomas I, Kihiczak GG, Schwartz A. Bedbug bites: a review. *Int J Dermatol* 2004;43(6):430-3.
2. Lindsay SW, Snow RW, Armstrong JR, Greenwood BM. Permethrin-impregnated bednets reduce nuisance arthropod in Gambian houses. *Med Vet Entomol* 1989;3(4):377-83.
3. Paul J, Bates J. Is infestation with the common bedbug increasing? *BMJ* 2000;320(7242):1141.
4. Romero A, Potter MF, Potter DA, Haynes KF. Insecticide resistance in the bed bug: a factor in the pest's sudden resurgence? *J Med Entomol* 2007;44(2):175-8.
5. Ter Poorten MC, Prose NS. The return of the common bedbug. *Pediatr Dermatol* 2005;22(3):183-7.
6. Elston DM, Stockwell S. What's eating you? Bedbugs. *Cutis* 2000;65(5):262-4.
7. Scarupa MD, Economides A. Bedbug bites masquerading as urticaria. *J Allergy Clin Immunol* 2006;117(6):1508-9.
8. Fletcher CL, Ardern-Jones MR, Hay RJ. Widespread bullous eruption due to multiple bed bug bites. *Clin Exp Dermatol* 2002;27(1):74-5.
9. Cestari TF, Martignago BF. Scabies, pediculosis, bedbugs, and stinkbugs: uncommon presentations. *Clin Dermatol* 2005;23(6):545-54.
10. Schwartz RA, Gorkiewicz-Petkow A. Bedbug bites. *eMedicine* 2010 Mar 24. Available from: <http://emedicine.medscape.com/article/1088931-overview>. Accessed 2010 Apr 16.