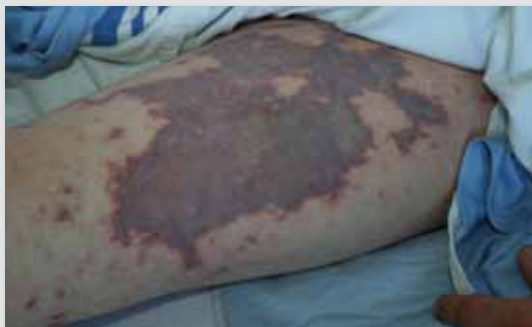

Dermacase



Can you identify this condition?

Brent M. McGrath MD MSc PhD
Christian Petropolis MD Peter West MD FRCPC

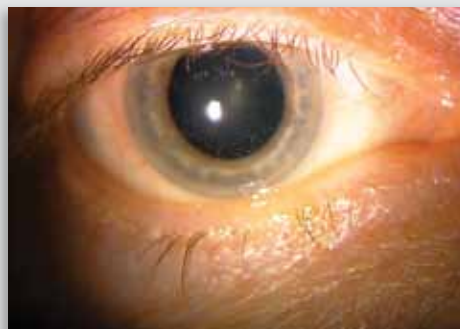
A 38-year-old man presented with a 1-day history of fever, chills, and diarrhea, with a petechial rash over his trunk, arms, and legs. His condition quickly deteriorated to septic shock, and the rash developed into widespread, large, ecchymotic lesions with diffuse purpura.

The most likely diagnosis is

1. Neutrophilic vasculitis
2. Rocky Mountain spotted fever
3. Meningococemia
4. Viral exanthem
5. Gonococemia

Answer on page 895

Ophthalmoproblem



Can you identify this condition?

Amaka A. Eneh Kelly D. Schweitzer MD
Todd Urton MD

A 50-year-old woman presents with a 4-day history of a sensation of pressure around the left eye, along with periorbital redness and photophobia. Visual acuity is 20/20 in the right eye and 20/50 in the left eye. Pupil examination reveals a sluggish but reactive left pupil, and no relative afferent pupillary defect is observed with the swinging flashlight test. Measurement of intraocular pressure by applanation tonometry is 18 mm Hg bilaterally. The corneal surface does not stain with fluorescein. The patient does not have a palpable left or right preauricular lymph node. She has no ocular history of note, and has had no ocular surgeries or trauma. Her medical, family, and medication histories are noncontributory. She denies any occurrence of skin rashes, joint pains, bowel or bladder symptoms, mouth or genital ulcers, fever, chills, night sweats, or weight loss, but does note increasing shortness of breath, dry cough, and chest discomfort.

The most likely diagnosis is

1. Corneal ulcer
2. Angle closure glaucoma
3. Acute anterior granulomatous uveitis
4. Viral conjunctivitis

Answer on page 896