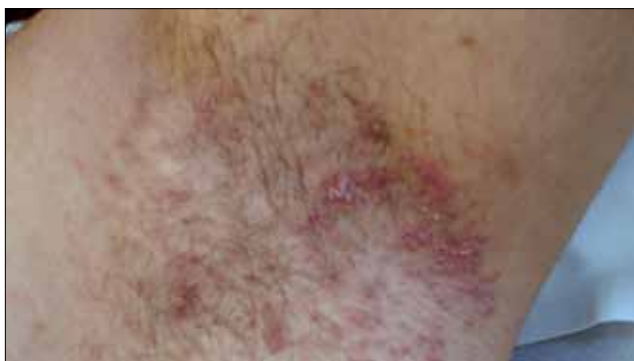
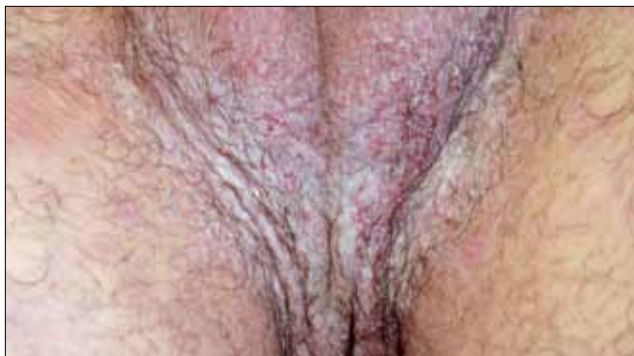
Dermacase



Can you identify this condition?

Lina Abdullah RN Ossama Abbas MD

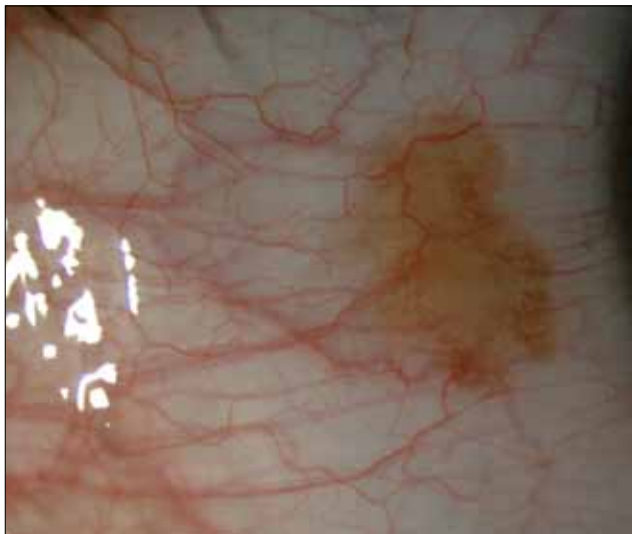
A 30-year-old man presents with a 2-week history of pruritic skin lesions involving the axillary and groin areas. The lesions have been recurring over the past 7 years. The rash is usually exacerbated by exposure to heat or sweating. Previous treatments, including topical glucocorticoids, antibiotics, and antifungals, have provided only minimal or partial relief. His brother has similar symptoms. Examination of the areas reveals multiple tender, erythematous, macerated patches, with erosions and fissures.

The most likely diagnosis is

1. Tinea cruris
2. Hidradenitis suppurativa
3. Benign familial chronic pemphigus
4. Intertrigo

Answer on page 1158

Ophthaprobem



Can you identify this condition?

Omar Rayward MD Paula Moreno-Martín MD
Jose Luis Vallejo-García MD Sergio Vano-Galvan PhD

A 12-year-old boy presented to the clinic for a routine ophthalmologic checkup. During the examination, a small, dark lesion was observed on the bulbar conjunctiva of his left eye. He did not complain of any ocular symptoms and mentioned that the dark lesion had been there for the past 2 years. He denied taking any medications and he did not have any systemic symptoms.

His visual acuity was 20/20 in both eyes. Slit lamp examination revealed a sessile, brownish, elevated lesion with clear cysts located at the temporal interpalpebral conjunctiva, very close to the limbus. Pupils, extraocular movements, intraocular pressure, and results of fundoscopy were normal. The patient indicated that the lesion had not grown in the past 2 years and that he had not noticed any change in colour. The patient was otherwise healthy.

The most likely diagnosis is

1. Conjunctival melanoma
2. Conjunctival nevus
3. Primary acquired melanosis
4. Pterygium

Answer on page 1159