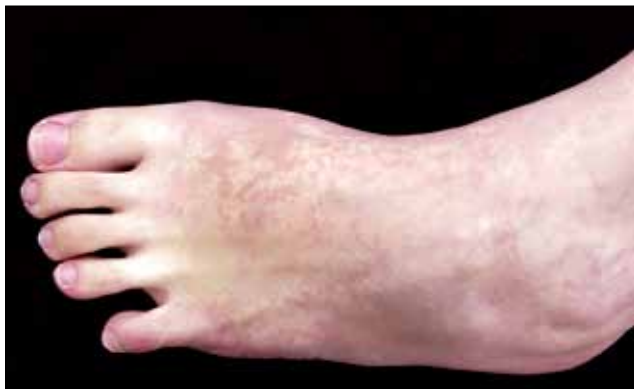

Dermacase



Can you identify this condition?

Jeng-Feng Chen MD Chien-Ping Chiang MD

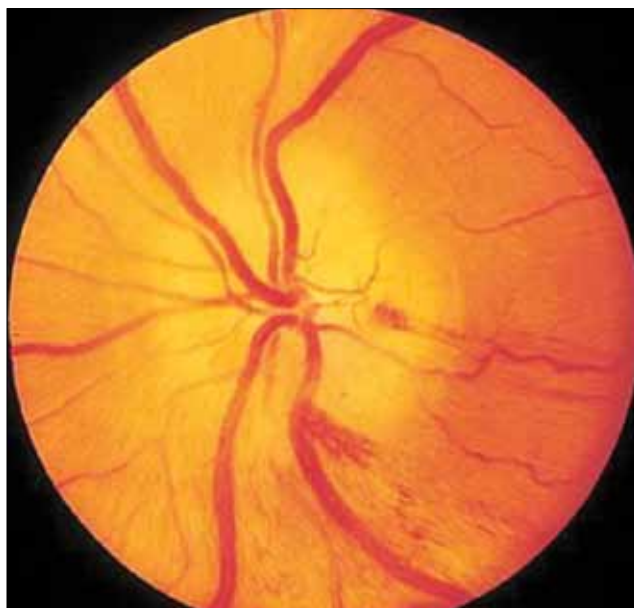
A 36-year-old woman presents with an asymptomatic, hypopigmented skin lesion on her left foot, which has been there since birth. Physical examination reveals an irregularly marginated whitish patch with peripheral islands of normal skin on the dorsal aspect of the foot. Scratching both the normal and affected skin produces erythema in the normal skin but not within the lesion. Her medical history is unremarkable and members of her family are not similarly afflicted.

The most likely diagnosis is

1. Vitiligo
2. Nevus depigmentosus
3. Nevus anemicus
4. Tinea versicolor
5. Tuberous sclerosis

Answer on page 1294

Ophthaprobem



Can you identify this condition?

Zac Feilchenfeld MD Edward Margolin MD FRCSC

A 78-year-old woman presents with a 1-day history of blurred vision in the right eye. She experienced the change suddenly and without any warning. She has also noticed a loss of appetite, a 5-kg weight loss, and headaches and pain in the neck and shoulder regions over the past 2 months. Upon questioning, she admits to pain in the jaw while chewing and scalp sensitivity (ie, tenderness to touch).

On examination, visual acuity is 20/25 in the left eye and she sees only hand motion in the right eye; there is a right relative afferent papillary defect. Results of fundoscopy reveal optic disk edema that has a chalky white colour. The left optic nerve appears normal. Both erythrocyte sedimentation rate and C-reactive protein levels are markedly elevated.

The most likely diagnosis is

1. Nonarteritic anterior ischemic optic neuropathy
2. Papilledema
3. Optic neuritis
4. Temporal arteritis

Answer on page 1296