Answer to Dermacase *continued from* ***page 766***

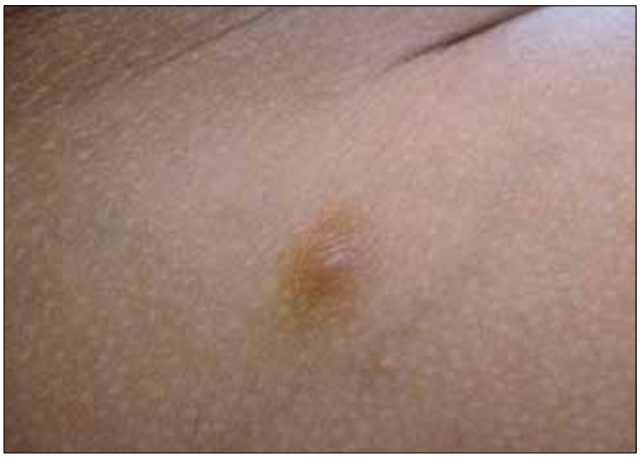

2. Solitary mastocytoma

Mastocytosis is a disorder characterized by abnormal growth and an increased number of mast cells in 1 or more organs.[1-5] In children, mastocytosis is most commonly limited to the skin (cutaneous mastocytosis) and is often transient compared with mastocytosis in adults.[1-5] Three forms of cutaneous mastocytosis are usually recognized in children: urticaria pigmentosa, mastocytoma, and diffuse cutaneous mastocytosis.[1-5] Mastocytoma typically presents at birth or develops within the first month of life as solitary or, occasionally, multiple red to brown macules, plaques, or nodules.[1-5] It rarely occurs in adults. When the lesion is rubbed or traumatized, swelling, mild tenderness, and even bullae formation can occur, a reaction known as Darier sign.[1-5] Extracutaneous involvement is rare. Lesions usually resolve spontaneously as the patient grows older.[1-5]

Histopathology reveals diffuse infiltration of the upper dermis and monomorphous, mononuclear mast cells with centrally located oval nuclei. Demonstration of metachromatic purple granules in the cytoplasm using Giemsa stain confirms the diagnosis.[1-5]

Differential diagnosis

The clinical differential diagnosis of solitary mastocytoma includes congenital melanocytic nevus, insect bite, and epidermal cyst.[6-8] Congenital melanocytic nevi commonly contain a junctional component, resulting in pigmentation.[6] Insect bites are acute and present as erythematous papules with scaling, crusting, or a central punctum.[7] Epidermal cysts are slow-growing, round, soft nodules that develop on the head, neck, and trunk.[8] In difficult cases, histologic examination is required to confirm diagnosis.

Management

The first step in the management of solitary mastocytoma is to exclude systemic involvement.[1-5] This can be achieved by performing a complete physical examination, paying special attention to the liver, spleen, and lymph nodes, and by requesting a laboratory workup that includes a complete blood count. In the absence of systemic involvement, local treatment can then be addressed.

For solitary mastocytoma, surgical excision remains a simple, rapid, and effective treatment, as was the case with our patient.[2,4,5] Intralesional steroid injections have also been reported to be useful.[3] In cases of multiple lesions, antihistamines, cromolyn sodium, or nonsteroidal anti-inflammatory agents can be used, in addition to avoidance of trigger factors such as temperature changes, trauma, and radiocontrast media.

Ms Abdullah was a registered nurse in the Department of Nursing at the American University of Beirut in Lebanon. **Dr Abbas** is Assistant Professor of Clinical Dermatology in the Department of Dermatology at the American University of Beirut.

Competing interests
None declared

References

1. Soter NA. Mastocytosis and the skin. *Hematol Oncol Clin North Am* 2000;14(3):537-55.
2. Ashinoff R, Soter NA, Freedberg IM. Solitary mastocytoma in an adult. Treatment by excision. *J Dermatol Surg Oncol* 1993;19(5):487-8.
3. Kang NG, Kim TH. Solitary mastocytoma improved by intralesional injections of steroid. *J Dermatol* 2002;29(8):536-8.
4. Kiszewski AE, Durán-Mckinster C, Orozco-Covarrubias L, Gutiérrez-Castrellón P, Ruiz-Maldonado R. Cutaneous mastocytosis in children: a clinical analysis of 71 cases. *J Eur Acad Dermatol Venereol* 2004;18(3):285-90.
5. Briley LD, Phillips CM. Cutaneous mastocytosis: a review focusing on the pediatric population. *Clin Pediatr* (Phila) 2008;47(8):757-61. Epub 2008 May 23.
6. Marghoob AA, Borrego JP, Halpern AC. Congenital melanocytic nevi: treatment modalities and management options. *Semin Cutan Med Surg* 2007;26(4):231-40.
7. Young PM, Bancroft LW, Peterson JJ, Roberts CC, Liu PT, Zaleski CG. Imaging spectrum of bites, stings, and their complications: pictorial review. *AJR Am J Roentgenol* 2009;193(3 Suppl):S31-41.
8. Jenkins JR, Morgan MB. Dermal cysts: a dermatopathological perspective and histological reappraisal. *J Cutan Pathol* 2007;34(11):815-29.