

# Delayed diagnosis of hip dislocation in a young child

J. Alexandra Mortimer MD Anne Dzus MD FRCSC

In young children, traumatic hip dislocation can occur after seemingly minor trauma. Here we present the case of a 4-year-old girl with delayed diagnosis of a hip dislocation to highlight the importance of examining the hips of young children who present with knee pain following low-energy trauma.

## Case

A 4-year-old girl injured her left leg while tobogganing. She complained of immediate pain in her left knee and refused to bear weight through her left lower extremity. Her family brought her to the local emergency department where radiographs of the left knee were obtained; radiographic findings of the knee were normal (**Figure 1**). It was believed that the patient had a soft tissue injury to the knee, and she was discharged home.

The patient continued to complain of discomfort in the left knee and refused to bear weight. The family returned to the emergency department 10 days after the initial injury for re-assessment. Bilateral knee radiographic findings were again normal. The diagnosis of a soft tissue injury to the knee remained. However, for a further 4 weeks, the patient continued to describe knee pain and would not bear weight.

At follow-up 6 weeks after injury, a radiograph of the pelvis was obtained and revealed a dislocation of the left hip (**Figure 2**). An urgent referral was made to the pediatric orthopedic surgeon on call. The

pediatric orthopedic team's assessment revealed the following: the patient had limited abduction of the left hip to 30°, a positive Galeazzi sign (unequal knee heights suggesting unilateral hip dislocation), and normal neurologic examination findings for the left lower extremity (**Figures 3 and 4**). A magnetic resonance imaging scan of the pelvis was performed immediately to assess the soft tissues around the dislocated hip and to assist with preoperative planning. It revealed a posterior and superolateral left hip dislocation with the femoral head protruding through the posterior hip capsule. There was no evidence of osteonecrosis. The patient was taken to the operating room for urgent management of her dislocated hip. Under general anesthesia, a closed reduction failed.

An open reduction was performed using a posterior approach. The femoral head was buttonholed through the posterior hip capsule (**Figure 5**). The joint was filled with thick fibrous tissue, and a small osteochondral defect was found in the posterior acetabulum. The hip was reduced. An adductor tenotomy was performed to help maintain the reduction, and a hip spica cast was applied (**Figure 6**). The patient was discharged home when she was comfortable.

She remained in the spica cast for 5 weeks. At her 9-month follow-up appointment, the patient had full range of motion in her hips and was walking well. Radiographic findings completed at follow-up revealed medial joint space widening and flattening of the epiphysis without fragmentation, similar to early Legg-Calvé-Perthes disease (**Figure 7**).

### EDITOR'S KEY POINTS

- A high index of suspicion for hip dislocation is necessary in children who present with knee pain after low-energy trauma.
- Most traumatic hip dislocations should be reduced under adequate sedation and muscle relaxation within 6 hours of injury to reduce the risk of femoral head osteonecrosis.
- Missed traumatic hip dislocations are best managed with open reduction under general anesthesia.

### POINTS DE REPÈRE DU RÉDACTEUR

- Il faut soupçonner fortement une dislocation de la hanche chez les enfants qui souffrent de douleurs au genou après un traumatisme à faible impact.
- La plupart des dislocations de la hanche doivent être réduites sous sédation suffisante et en présence d'une relaxation musculaire adéquate dans les 6 heures suivant la blessure pour réduire le risque d'ostéonécrose de la tête fémorale.
- Il vaut mieux prendre en charge les dislocations traumatiques de la hanche passées inaperçues au moyen d'une réduction chirurgicale sous anesthésie générale.

This article has been peer reviewed.

Cet article a fait l'objet d'une révision par des pairs.

*Can Fam Physician* 2016;62:815-7

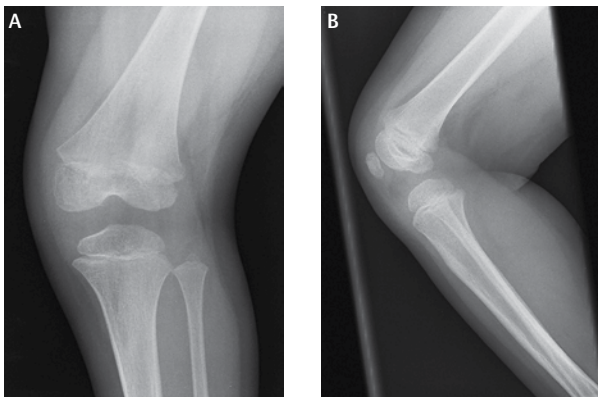
### Discussion

Traumatic hip dislocations are an uncommon injury in children. A delay in diagnosis might lead to complications, the most important being osteonecrosis of the femoral head. Owing to relative laxity in young children, low-energy trauma (eg, tobogganing) is all that is needed to cause a hip dislocation, unlike the high-energy mechanism required for such an effect in adolescents or adults.<sup>1</sup> Most dislocations will be posterior. On examination the affected lower extremity will be in hip flexion, adduction, and internal rotation for a posterior dislocation. The opposite is true in the case of an anterior dislocation, in which hip extension, abduction, and external rotation are visible. Any abnormal positioning of the lower limb or limb-length discrepancy (a positive Galeazzi sign) should alert the physician to the possibility of a hip dislocation. A neurovascular examination should be performed to assess for associated injuries.

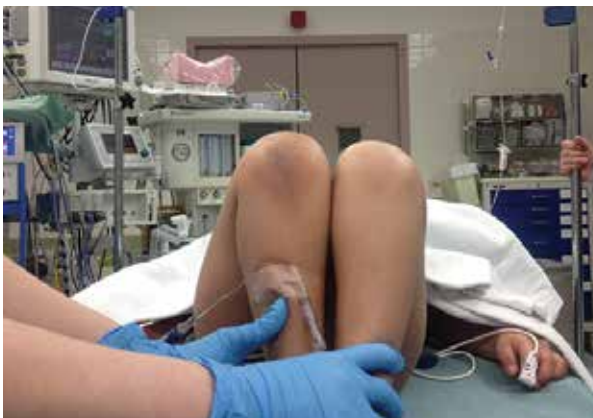The treating physician should order anteroposterior pelvis and frog-leg lateral radiographs in any child suspected of having a traumatic hip dislocation; this will determine the presence of a dislocation, the direction of dislocation, and any associated injuries or fractures. For cases in which children complain of knee pain after low-energy trauma and radiographic findings of the knee are normal, one should have a low threshold to image the pelvis. Children often have difficulty localizing pain and might complain of pain elsewhere in the lower extremity when presenting with a hip dislocation.

Most traumatic hip dislocations should be reduced under adequate sedation and muscle relaxation within 6 hours of injury to reduce the risk of femoral head osteonecrosis.<sup>2</sup> The incidence of osteonecrosis after isolated hip dislocation in those younger than age 18 ranges from 3% to 15%.<sup>1,2</sup> This risk is increased 20-fold when the reduction is delayed beyond 6 hours.<sup>2</sup> Most hips will reduce with gentle traction.

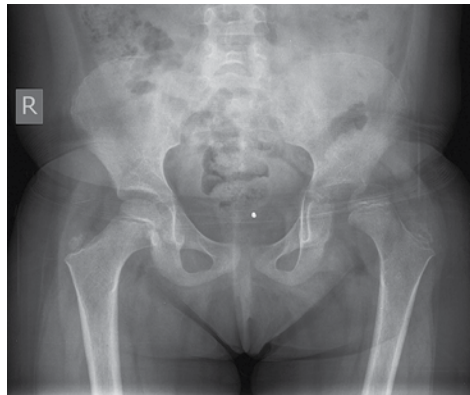**Figure 1.** Plain film radiographs of the patient's left knee at the time of injury revealing normal findings: A) anteroposterior view; B) lateral view.



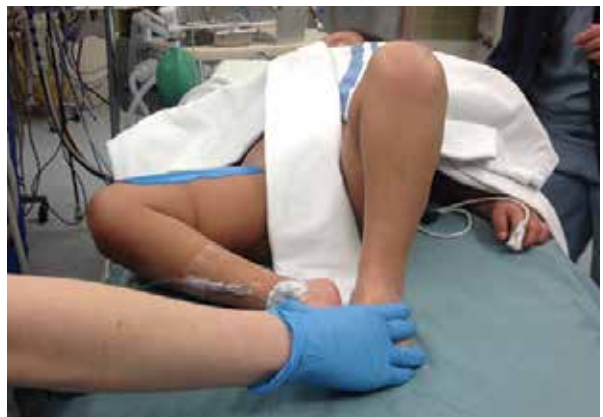**Figure 3.** Intraoperative photograph demonstrating a positive Galeazzi sign



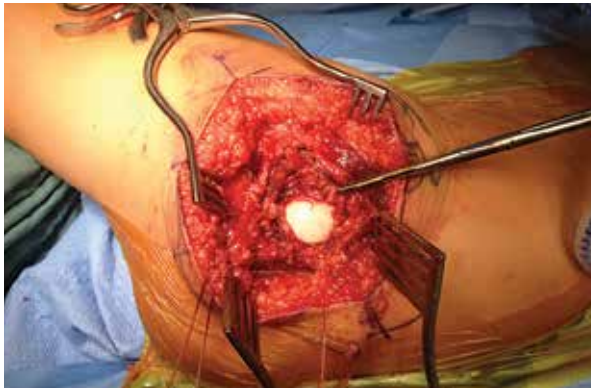
**Figure 2.** Plain film radiograph of the anteroposterior view of the pelvis 6 weeks after injury confirming a left hip dislocation



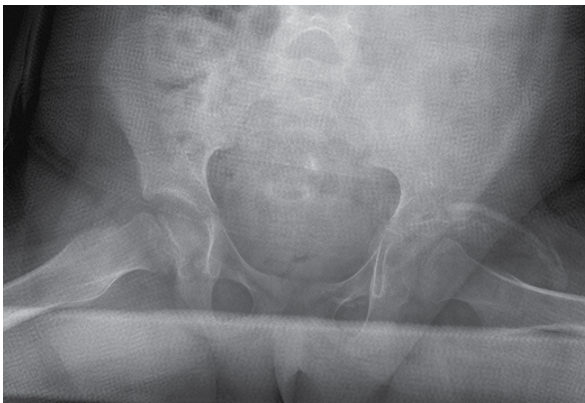
**Figure 4.** Intraoperative photograph demonstrating markedly decreased abduction of the left hip



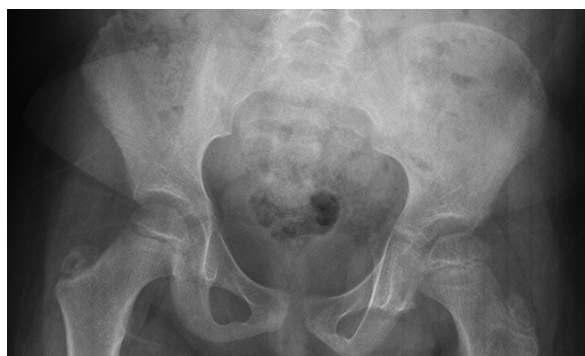**Figure 5.** Femoral head buttonholed through the posterior hip capsule during the open reduction of the left hip using the posterior approach



**Figure 6.** Postoperative plain film radiograph of the anteroposterior view of the hip in the spica cast with the left hip concentrically reduced



**Figure 7.** Plain film radiograph of the anteroposterior view of the pelvis at 9 months' follow-up: There is medial joint space widening with slight lateral subluxation of the hip and flattening of the femoral epiphysis. Note the disruption in Shenton line.




After 1 or 2 attempts at gentle closed reduction, open reduction under general anesthesia should be undertaken. The approach should be from the direction of the dislocation.<sup>3</sup> Barquet<sup>4</sup> reviewed the natural history of 145 cases of hip dislocation in children and found that in those younger than age 12, the changes observed resemble Legg-Calvé-Perthes disease while in those older than age 12, they start to resemble avascular necrosis of the femoral head as seen in adults.

Open reduction is recommended for the management of missed dislocation. In one study of 18 missed posterior hip dislocations, all of the hips were treated with open reduction because none of the hips could be reduced by skeletal traction alone.<sup>5</sup> In this study, all of the hips had fibrous tissue in the acetabulum at the time of open reduction. At 2 years' follow-up, 17 had excellent functional outcomes.<sup>5</sup> Open reduction helps to replace the femoral head in its anatomic position providing a stimulus for growth of the pelvis and femur. A review of 8 missed dislocations that were treated with open reduction at a mean of 12 months after injury demonstrated that 7 had radiographic features of avascular necrosis. Despite poor radiographic outcomes, all 8 patients had good functional outcomes at a mean follow-up of 7 years.<sup>6</sup>

Despite the high radiographic incidence of femoral head osteonecrosis after missed traumatic hip dislocation, it appears that patients function well after open reduction of the hip. It is imperative that these injuries be identified early to prevent osteonecrosis of the femoral head. Management of hip dislocation at the time of presentation is gentle closed reduction under adequate sedation and muscle relaxation.

## Conclusion

Having a high index of suspicion and examining the hips of young children who present with knee pain after minor trauma is critical to long-term prognosis. Open reduction remains the treatment of choice for missed traumatic hip dislocation. 

**Dr Mortimer** is a resident in the Division of Orthopedic Surgery at the University of Saskatchewan in Saskatoon. **Dr Dzus** is Director of Pediatric Surgical Services in the Division of Orthopedic Surgery at the University of Saskatchewan.

### Competing interests

None declared

### Correspondence

Dr J. Alexandra Mortimer; e-mail [mortimer.alexandra@gmail.com](mailto:mortimer.alexandra@gmail.com)

### References

- Vialle R, Odent T, Pannier S, Pauthier F, Laumonier F, Glorion C. Traumatic hip dislocation in childhood. *J Pediatr Orthop* 2005;25(2):138-44.
- Barquet A, Hubbard GW, Crawford AH, Roy DR, Wall EJ. Traumatic hip dislocation in children: long-term followup of 42 patients. *Clin Orthop Relat Res* 2000;376:68-79.
- Herrera-Soto JA, Price CT. Traumatic hip dislocations in children and adolescents: pitfalls and complications. *J Am Acad Orthop Surg* 2009;17(1):15-21.
- Barquet A. Natural history of avascular necrosis following traumatic hip dislocation in childhood: a review of 145 cases. *Acta Orthop Scand* 1982;53(5):815-20.
- Kumar S, Jain AK. Neglected traumatic hip dislocation in children. *Clin Orthop Relat Res* 2005;431:9-13.
- Banskota AK, Spiegel DA, Shrestha S, Shrestha OP, Rajbhandary T. Open reduction for neglected traumatic hip dislocation in children and adolescents. *J Pediatr Orthop* 2007;27(2):187-91.